



Diagnosis of Gastroesophageal Reflux Disease in the Practice of an Otorhinolaryngologist: Association Between Chronic Pathology of the Pharynx and Larynx in Disease

Arbi Ruslanovich Bitayev^{1*}, Vakhtmurad Vakharbievich Chagaev², Askhab Anzorovich Khambiev³, Magomed Iusupovich Magomedov³, Mokhammad Musaevich Temirsultanov³, Magomed Nasukhovich Azizov³, Kheda Magomedovna Kurbanova⁴, Arianna Zaurbegovna Gadzhimuradova⁵, Liana Gagikovna Soloyan³, Khava Said-Aminovna Tolkhigova⁶

¹ Saratov State Medical University named after V.I. Razumovsky, Saratov, RUSSIA.

² MEDSI JSC, Moscow, RUSSIA.

³ Rostov State Medical University, Rostov-on-Don, RUSSIA.

⁴ North Ossetian State Medical Academy, Vladikavkaz, Republic of North Ossetia-Alania, RUSSIA.

⁵ Dagestan State Medical University, Makhachkala, Republic of Dagestan, RUSSIA.

⁶ Chechen State University named after A.A. Kadyrov, Grozny, Republic of Chechnya, RUSSIA.

*Corresponding Author (Tel: +79183500889, Email: ruslankalmykov777@yandex.ru)

Paper ID: 13A11N

Volume 13 Issue 11

Received 08 February 2022

Received in revised form 08

July 2022

Accepted 15 July 2022

Available online 23 July

2022

Keywords:

Gastroesophageal reflux disease;

Pharyngolaryngeal

reflux; Symptoms of

GERD; Symptoms of

pharyngolaryngeal

reflux

Abstract

Gastroesophageal reflux disease (GERD) is a chronic disease with frequent relapses. Advanced forms of the disease lead to a deterioration in the quality of life of the patient, to prolonged medication or surgical treatment. In addition, there is a problem of the unidentification of GERD due to blurred symptoms and complaints of bronchopulmonary and/or cardiological symptoms, symptoms similar to diseases with which it is customary to contact ENT specialists. In this article, the authors collected information from published scientific sources in order to facilitate the diagnosis of GERD against the background of non-specific symptoms for this disease and their differentiation from ENT diseases. The aim of the work was to create a "roadmap" of differentiation of ENT diseases from GERD.

Discipline: Medicine, Gastroenterology, Otorhinolaryngology

©2022 INT TRANS J ENG MANAG SCI TECH.

Cite This Article:

Bitayev, A.R., Chagaev, V.V., Khambiev, A.A., Magomedov, M.Iu., Temirsultanov, M.M., Azizov, M.N., ... Tolkhigova, Kh.S.-A. (2022) Diagnosis of GERD in the practice of an otorhinolaryngologist: association between chronic pathology of the pharynx and larynx in GERD. *International Transaction Journal of Engineering, Management, & Applied Sciences & Technologies*, 13(11), 13A11N, 1-8. <http://TUENGR.COM/V13/13A11N.pdf> DOI: 10.14456/ITJEMAST.2022.224

1 Introduction

According to various data, the prevalence of gastroesophageal reflux disease (GERD) among the adult population of Russia is 18-46%, and among children – 8,7 – 18%, and in childhood, the prevalence of GERD is almost impossible to accurately determine due to the lack of a systematic approach to detecting the disease, as well as the difficulty of identifying symptoms by young patients [1,2].

The definition of GERD was proposed in 2006 in Montreal: "a condition that develops in cases when throwing stomach contents into the esophagus causes disturbing symptoms and/or leads to the development of complications" [3].

Involuntary throwing of gastric contents into the esophagus causes physical and chemical damage to the lining of the esophagus. Extraesophageal symptoms involve the bronchopulmonary, cardiovascular systems, ENT organs, and teeth of the patient in the pathological process.

2 Literature Review

GERD is mentioned in many sources as a concomitant pathology in bronchial asthma, chronic bronchitis, otorhinolaryngology notes coughing, scratching, hoarse voice, ear pain, and in dentistry – the erosion of tooth enamel is recorded [4-8].

Table 1: Classification of extraesophageal clinical manifestations of GERD

Extraesophageal syndromes associated with GERD	
Confirmed	Presumably
Cough of reflux nature	Pharyngitis
Laryngitis of reflux nature	Sinusitis
Bronchial asthma of reflux nature	Idiopathic pulmonary fibrosis
Erosion of tooth enamel of reflux nature	Recurrent otitis media

GERD has been proven to be the cause of chronic dry cough in 45% of cases, and productive cough with sputum in 12% [9].

Table 2: Pathogenesis of GERD-induced cough

When exposed to gastric contents on the vagal receptors of the distal part of the esophagus	Cough reflex from laryngeal and tracheobronchial tree receptors with micro- or microaspiration of esophageal contents
Usually, a dry cough worsens during an upper respiratory tract infection, especially when the body position changes during the daytime.	
Microaspiration acts as a trigger for asthma attacks, especially at night.	

Otolaryngological symptoms of GERD: pain, coma, foreign body in the pharynx, tickling, hoarseness, paroxysmal cough [10-12].

3 Method

Laryngopharyngeal reflux is the entry of gastric contents into the larynx and pharynx, which is not physiological in relation to the epithelium of the pharynx and larynx. Patients turn to a therapist or an otolaryngologist with complaints of the following symptoms:

- Hoarseness, which is expressed in the distortion of the usual timbre of the voice;
- Dysphonia, weakness or excessive volume of the voice;
- A feeling of tickling in the throat;
- Pain, burning sensation in the throat;
- Frequent and involuntary coughing;

- Chronic prolonged dry or productive cough;
- Feeling of a lump in the throat;
- Snoring (apnea);
- Laryngospasm – uncontrolled muscular contraction of the vocal folds;
- Swelling of the laryngopharyngeal mucosa;
- Postnasal congestion syndrome.

When referring a patient to a specialist with these complaints, prescribing adequate therapy for ENT diseases and persistent symptoms as a result of therapy, GERD should be suspected. For an adequate assessment of the patient's condition and before the appointment of laboratory or instrumental methods of investigation specific for GERD, a test should be performed to determine reflux symptoms. The risk assessment system for diagnosing GERD is measured on a 5-point scale, where 0 – there are no problems at all, 5 – indicates the presence of serious problems (Table 3).

Table 3: Questionnaire for determining reflux symptoms

How much have you been bothered by the following issues over the past month? (Rate your condition from 0 to 5, where 0 – no complaints, 5 – causes serious concern)
Hoarseness of voice.
Sore throat.
Expectoration of mucus or leakage of mucus along the back wall of the nasopharynx.
Cough after eating.
Difficulty swallowing food or pills/pills.
Difficulty breathing or suffocation.
Painful cough.
Feeling of a lump in the throat.
Heartburn, belching, chest pain.

The questionnaire is necessary in order to differentiate GERD from ENT pathologies. The number of points from 13 and above indicates GERD.

Sore throat, hoarseness, loss of voice, dry cough – the result of throwing gastric contents into the larynx. The method verifying the association of such symptoms with GER is 24-hour intraesophageal pH-impedancemetry. This method allows us to establish the presence of a correlation between the appearance of the symptom and reflux episodes (symptom index > 50%). An additional diagnostic method may be the determination of pepsin in saliva [13].

The epithelium of the pharynx and larynx is more sensitive to the damaging effect of gastric secretions and is less protected compared to the epithelium of the esophagus. Four physiological barriers are protecting the upper respiratory tract from the damaging effects of reflux: lower esophageal sphincter, esophageal clearance, esophageal tissue resistance, and upper esophageal sphincter. In addition, one of the most important protective mechanisms of the esophageal mucosa from the damaging effects of hydrochloric acid is the enzyme carbonic anhydrase, which catalyzes the hydration of carbon dioxide, leading to the formation of bicarbonate [14]. An active pump pumps bicarbonate into the extracellular space, where it neutralizes reflux hydrochloric acid. A low level of carbonic anhydrase is detected in the laryngeal mucosa; moreover, this enzyme is absent in 64% of tissue samples taken from patients with PLR [15]. As a result, the acidic contents of the

stomach and pepsin, being in the pharynx and larynx, are inactivated much longer. In this regard, GER penetrating through the upper esophageal sphincter will never be considered physiological, so even one episode of a decrease in pH <4 in the larynx is diagnosed as PLR (pharyngolaryngeal reflux).

The most common symptoms of PLR are hoarseness, which is found in 71% of patients, cough – in 51%, a lump in the throat – in 47%, and the desire to "clear the throat" – in 42% [16]. All these symptoms are not specific, they are mandatory for acute respiratory viral infections, professional voice load, allergic rhinitis, smoking and alcohol abuse.

Many experts suspect PLR in the pathogenesis of laryngeal diseases: vocal fold nodules, functional disorders of the vocal apparatus, contact ulcers and granulomas, Reinke's edema [17].

The negative effect of reflux on the mucous membrane of the posterior larynx provokes the appearance of contact granulomas and ulcers localized in the area of the vocal processes of the arytenoid cartilages. The influence of PLR on the development and course of diseases such as recurrent respiratory papillomatosis, cicatricial stenosis, malignant tumors of the larynx remains in the field of scientific discussions [18-20], and the participation of reflux in the pathogenesis of chronic diseases of the nose and paranasal sinuses has also not been proven. The mechanism explaining the association between PLR and sinusitis includes chronic irritation of the nasal mucosa and chronic adhesion of bacterial agents to the mucosa. However, there is no significant difference in the frequency of detection of acidic stomach contents in the oropharynx in patients suffering from vasomotor rhinitis and in healthy volunteers [21,22]. And although there is evidence of a high frequency of detection of reflux in the nasopharynx in patients suffering from chronic rhinosinusitis [23,24], other researchers believe that reflux does not play a significant role in the pathogenesis of this disease. The physiological basis of the possible effect of PLR on chronic inflammation of the auditory tube leading to otitis is also not definitively determined and is being debated. A possible mechanism may be inflammation of the nasopharyngeal mucosa, which leads to obstruction of the Eustachian tube, although it may be associated with a vagal reflex transmitted from the distal part of the esophagus through the pharyngeal nerve [25-27].

4 Result and Discussion

To differentiate the symptoms of GERD and PLR, a sufficient amount of information and observations of patients has been collected, which makes it possible to distinguish these symptoms from simple daily observations to laboratory tests (Table 4).

Despite the difference in clinical symptoms, the basic principles of GERD and PLR treatment are similar and are carried out in several directions:

- lifestyle changes,
- drug therapy,
- surgical correction.

Lifestyle changes:

- normalization of body weight;

- reduction of physical exertion, especially associated with bending the torso forward;
- dietary recommendations – frequent fractional meals, the last meal no later than a few hours before bedtime, stopping or sharply limiting the use of chocolate, coffee, tea, carbonated and other beverages containing caffeine, as well as products that increase gas formation, hot and spicy food, etc.;
- quitting smoking, taking alcoholic beverages;
- if possible – restriction or cancellation of medications that increase the acidity of the stomach or reduce the tone of smooth muscles (nitrates, theophylline, calcium antagonists, etc.).

Table 4: Differences in symptoms of gastroesophageal reflux disease and pharyngolaryngeal reflux

Index	Gastroesophageal reflux disease	Pharyngolaryngeal reflux
Body position	Horizontal	Vertical
Time of occurrence	At night	In the afternoon
Duration of GER	Prolonged exposure to acid	Short-term exposure to acid
Pathophysiology	Dysfunction of the lower esophageal sphincter, violation of esophageal motility	Dysfunction of the upper esophageal sphincter, normal motility of the esophagus
Symptoms	Mainly from the gastrointestinal tract	Mainly from the pharynx and larynx
Heartburn, regurgitation	Most have	Rarely
Lesion of the esophageal mucosa	Approximately 50% of patients	Practically not
PH-metric of the esophagus	Correlates	Does not correlate
Duration of therapy	3 months	From 6 months
Effectiveness of therapy	Rapid elimination of symptoms on the background of therapy	Slow relief of symptoms, unpredictability of therapy

The authors of this article believe that it will be useful for an ENT practitioner to have in his arsenal a kind of "roadmap" for identifying GERD and referring a patient to a gastroenterologist (Figure 1).

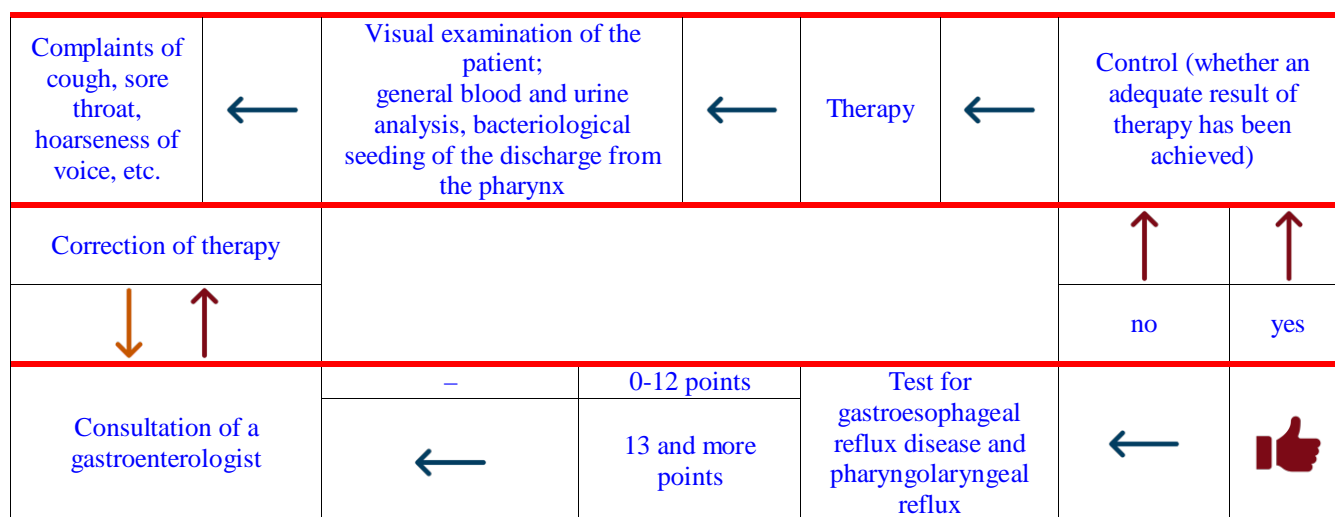


Figure 1: The "roadmap" of an otolaryngologist to exclude GERD

5 Conclusion

In this article, the authors collected information from published scientific sources in order to facilitate the diagnosis of GERD against the background of non-specific symptoms for this disease

and their differentiation from ENT diseases. The aim of the work was to create a "roadmap" of differentiation of ENT diseases from GERD.

GERD is mentioned in many sources as a concomitant pathology in bronchial asthma, chronic bronchitis, otorhinolaryngology notes coughing, scratching, hoarse voice, ear pain, in dentistry – the erosion of tooth enamel is recorded.

Despite the difference in clinical symptoms, the basic principles of GERD and PLR treatment are similar and are carried out in several directions: lifestyle changes, drug therapy, surgical correction.

6 Availability of Data and Material


Data can be made available by contacting the corresponding author.

7 References

- [1] Chen J, Brady P. Gastroesophageal Reflux Disease: Pathophysiology, Diagnosis, and Treatment. *Gastroenterol Nurs*. 2019 Jan/Feb;42(1):20-28. doi: 10.1097/SGA.0000000000000359
- [2] Boraeva, T. T., Vadaeva, M. A., Matveeva, U. V., Revazova, A. B., Albegova, B. Z., Kanukoeva, D. T., Mishvelov, A. E. and Povetkin, S. N. Dynamics of Diseases of the Upper Digestive Tract in Children, *Journal of Pharmaceutical Research International*, 2021; 33(38B), 48-57. doi: 10.9734/jpri/2021/v33i38B32098
- [3] Vakil, N.; Van Zanten, S.V.; Kahrilas, P.; Dent, J.; Jones, R.; Global Consensus Group. The Montreal definition and classification of gastroesophageal reflux disease: A global evidence-based consensus. *Am. J. Gastroenterol*. 2006, 101, 1900–1920
- [4] Raevskaya AI, Belyalova AA, Shevchenko PP, Karpov SM, Mishvelov AE, Simonov AN, Povetkin SN. et al. Cognitive Impairments in A Range of Somatic Diseases Diagnostics, Modern Approach to Therapy . *Pharmacophore*. 2020; 11(1):136-41
- [5] Galabueva AI, Biragova AK, Kotsoyeva GA, Borukayeva ZK, Yesiev RK, Dzgoeva ZG, et al. Optimization of Modern Methods of Treating Chronic Generalized Periodontitis of Mild Severity. *Pharmacophore*. 2020;11(1):47-51
- [6] Ilyasov KK, Demchenkov EL, Chernyshkov AS, Rodin IA, Pushkin SV, Povetkin SN, et al. Features of the phytopharmacological preparations in the metaphylaxis of urolithiasis. *Pharmacophore*. 2020;11(5):66-71
- [7] Sadyrin E, Swain M, Mitrin B, Rzhepakovsky I, Nikolaev A, Irkha V, Yogina D, Lyanguzov N, Maksyukov S, Aizikovich S. Characterization of Enamel and Dentine about a White Spot Lesion: Mechanical Properties, Mineral Density, Microstructure and Molecular Composition. *Nanomaterials (Basel)*. 2020;10(9):1889. DOI: 10.3390/nano10091889
- [8] RzhepakovskyI., SiddiquiS.A., AvanesyanS., BenlidayiM., DhingraK., DolgalevA., EnukashvilyN., FritschT., HeinzV., KocherginS., NagdalianA., SizonenkoM., TimchenkoL., VukovicM., PiskovS., GrimmW-D. Anti- arthritic effect of chicken embryo tissue hydrolyzate against adjuvant arthritis in rats (X- ray microtomographic and histopathological analysis). *Food Science & Nutrition*. 2021;00:1-22.DOI: 10.1002/fsn3.2529
- [9] Poddar U. Gastroesophageal reflux disease (GERD) in children. *Paediatr Int Child Health*. 2019 Feb;39(1):7-12. doi: 10.1080/20469047.2018.1489649.
- [10] Bledzhyants GA, Mishvelov AE, Nuzhnaya KV, Anfinogenova OI, Isakova JA, Melkonyan RS. The Effectiveness of the medical decision-making support system “electronic clinical pharmacologist” in the

management of patient's therapeutic profile. *Pharmacophore*. 2019;10:76-81

- [11] Hite GJ, Mishvelov AE, Melchenko EA, Vlasov AA, Anfinogenova OI, Nuzhnaya CV, et al. Holodoctor planning software real-time surgical intervention. *Pharmacophore*. 2019;10(3):57-60
- [12] Dmitry AnatolyevichDomenyuk, Vladimir AlexandrovichZelensky, Igor Vladimirovich Rzhepakovsky, Oksana Ivanovna Anfinogenova, Application of Laboratory and X-Ray Genral Studies un Early Diagnostics of Metabolic Disturbances of Bone Tissue in Children with Autoimmune Diabetes Mellitus , *Entomol Appl Sci Lett*. 2018;5(4):1-12
- [13] Jurkiewicz D, Waśko-Czopnik D, Pietruszewska W, Tarnowski W, Barańska M, Kowalczyk M, Jaworski P. Gastroesophageal reflux disease - from the point of view of a gastroenterologist, otolaryngologist and surgeon. *Otolaryngol Pol*. 2021 Apr 30;75(2):42-50. doi: 10.5604/01.3001.0014.8478.
- [14] Kurin M, Shibli F, Kitayama Y, Kim Y, Fass R. Sorting out the Relationship between Gastroesophageal Reflux Disease and Sleep. *Curr Gastroenterol Rep*. 2021 Aug 2;23(9):15. doi: 10.1007/s11894-021-00815-4.
- [15] Axford SE, Sharp N, Ross PE, Pearson JP, Dettmar PW, Panetti M, Koufman JA. Cell biology of laryngeal epithelial defenses in health and disease: preliminary studies. *Ann Otol Rhinol Laryngol*. 2001 Dec;110(12):1099-108. doi: 10.1177/000348940111001203.
- [16] Johnston N, Bulmer D, Gill GA, Panetti M, Ross PE, Pearson JP, Pignatelli M, Axford SE, Dettmar PW, Koufman JA. Cell biology of laryngeal epithelial defenses in health and disease: further studies. *Ann Otol Rhinol Laryngol*. 2003 Jun;112(6):481-91. doi: 10.1177/000348940311200601.
- [17] Ylitalo R, Ramel S. Extraesophageal reflux in patients with contact granuloma: a prospective controlled study. *Ann Otol Rhinol Laryngol*. 2002 May;111(5 Pt 1):441-6. doi: 10.1177/000348940211100509
- [18] Halstead LA. Gastroesophageal reflux: A critical factor in pediatric subglottic stenosis. *Otolaryngol Head Neck Surg*. 1999 May;120(5):683-8. doi: 10.1053/hn.1999.v120.a91766
- [19] Qadeer MA, Colabianchi N, Vaezi MF. Is GERD a risk factor for laryngeal cancer? *Laryngoscope*. 2005 Mar;115(3):486-91. doi: 10.1097/01.mlg.0000157851.24272.41.
- [20] Vaezi MF, Qadeer MA, Lopez R, Colabianchi N. Laryngeal cancer and gastroesophageal reflux disease: a case-control study. *Am J Med*. 2006 Sep;119(9):768-76. doi: 10.1016/j.amjmed.2006.01.019.
- [21] Geterud A, Bove M, Ruth M. Hypopharyngeal acid exposure: an independent risk factor for laryngeal cancer? *Laryngoscope*. 2003 Dec;113(12):2201-5. doi: 10.1097/00005537-200312000-00030.
- [22] Shaker R, Bardan E, Gu C, Kern M, Torrico L, Toohill R. Intrapharyngeal distribution of gastric acid refluxate. *Laryngoscope*. 2003 Jul;113(7):1182-91. doi: 10.1097/00005537-200307000-00014
- [23] Wong IW, Omari TI, Myers JC, Rees G, Nair SB, Jamieson GG, Wormald PJ. Nasopharyngeal pH monitoring in chronic sinusitis patients using a novel four channel probe. *Laryngoscope*. 2004 Sep;114(9):1582-5. doi: 10.1097/00005537-200409000-00015
- [24] Tovlahanova TJH et al. Study of the Effect of the Image Scanning Speed and the Type of Conductive Coating on the Quality of Sem-Micrographs of Oxide Nano Materials for Medical Use. *Ann Med Health Sci Res*. 2021;11:S3:60-64
- [25] Khandia, Rekha et al. Codon Usage Analysis of Pro-Apoptotic Bim Gene Isoforms. 2022: 1711-1725
- [26] Siddiqui SA, Ali Redha A, Snoeck ER, Singh S, Simal-Gandara J, Ibrahim SA, Jafari SM. Anti-Depressant Properties of Crocin Molecules in Saffron. *Molecules*. 2022; 27(7):2076. DOI: 10.3390/molecules27072076




Arbi Ruslanovich Bitayev is a student of Saratov State Medical University named after V.I.Razumovsky, Saratov, Russia



Dr. Vakhmurad Vakharbievich Chagaev is an Otorhinolaryngologist, MEDSI JSC, Moscow, Russia



Askhab Anzorovich Khambiev is a student of Rostov State Medical University, Rostov-on-Don, Russia




Magomed Iusupovich Magomedov is a student of Rostov State Medical University, Rostov-on-Don, Russia




Mokhammad Musaevich Temirsultanov is a student of Rostov State Medical University, Rostov-on-Don, Russia




Magomed Nasukhovich Azizov is a student of Rostov State Medical University, Rostov-on-Don, Russia




Kheda Magomedovna Kurbanova is a student of the North Ossetian State Medical Academy, Vladikavkaz, Republic of North Ossetia-Alania, Russia



Arianna Zaurbegovna Gadzhimuradova is a student of Dagestan State Medical University, Makhachkala, Republic of Dagestan, Russia



Liana Gagikovna Soloyan is a student of Rostov State Medical University, Rostov-on-Don, Russia



Khava Said-Aminovna Tolkhigova is a student of the Chechen State University named after A.A. Kadyrov, Grozny, Republic of Chechnya, Russia