



# Uterine Fibroid in Combination with Adenomyosis. Purulent-Inflammatory Diseases of the Female Genital Organs and Their Effect on Reproductive Function

Irina Petrovna Mikhailiuk<sup>1</sup>, Yuliya Alexandrovna Shandanovina<sup>1</sup>, Djamilya Gadjibalaevna Ramazanova<sup>2</sup>, Anfisa Andreevna Brynza<sup>3</sup>, Khadizhat Shakhbanovna Dzhalaeva<sup>2</sup>, Rukiyat Shamilevna Abdulaeva<sup>2</sup>, Khapta Masautovna Adasheva<sup>4</sup>, Amina Alibekovna Rashidova<sup>2</sup>, Linda Masudovna Abzailova<sup>5</sup>, Elina Kazbek-Sultanovna Katchieva<sup>5</sup>

<sup>1</sup> Rostov State Medical University, Rostov-on-Don, RUSSIA.

<sup>2</sup> Dagestan State Medical University, Makhachkala, Republic of Dagestan, RUSSIA.

<sup>3</sup> Stavropol State Medical University, Stavropol, RUSSIA.

<sup>4</sup> Chechen State University named after A.A. Kadyrov, Grozny, Republic of Chechnya, RUSSIA.

<sup>5</sup> Kabardino-Balkarian State University named after H.M. Berbekov, Nalchik, Republic of Kabardino-Balkaria, RUSSIA.

\*Corresponding Author (Tel: +79183500889, Email: [ruslankalmykov777@yandex.ru](mailto:ruslankalmykov777@yandex.ru)).

**Paper ID: 13A11J**

**Volume 13 Issue 11**

Received 03 April 2022

Received in revised form 06 July 2022

Accepted 13 July 2022

Available online 20 July 2022

## Keywords:

Uterine fibroids, Adenomyosis, Purulent-inflammatory diseases of the female genital organs, Infections, Reproductive function.

## Abstract

Uterine fibroids in combination with adenomyosis are common gynecological diseases. According to various studies, uterine fibroids are diagnosed in women of reproductive age in 30-40% of cases, adenomyosis occurs in 15-50% of cases in patients of any age, and the combination of uterine fibroids with adenomyosis occurs in 36-83% of cases. Despite the prevalence of these diagnoses, the first place among diseases of the female genital sphere is occupied by purulent-inflammatory diseases of the female genital organs, leading to hospitalization in gynecological hospitals in 20-30% of cases, causing ectopic pregnancy in 15% of cases, causing infertility in 45-78% of cases. The relevance of this study is due to the prevalence of purulent-inflammatory diseases of the female genital organs and benign hyperplastic diseases of the uterus among women of reproductive age, which contributes to the study of the effect of the purulent-inflammatory process on the pathogenesis of uterine fibroids in combination with adenomyosis and reproductive function in women.

**Discipline:** Medicine (Gynecology).

©2022 INT TRANS J ENG MANAG SCI TECH.

## Cite This Article:

Mikhailiuk, I.P., Shandanovina, Yu.A., Ramazanova, Dj.G., Brynza, A.A., Dzhalaeva, Kh. Sh., Abdulaeva, R.Sh., ... Katchieva, E.K.-S. (2022) Uterine fibroid in combination with adenomyosis. Purulent-inflammatory diseases of the female genital organs and their effect on reproductive function. *International Transaction Journal of Engineering, Management, & Applied Sciences & Technologies*, 13(11), 13A11J, 1-10. <http://TUENGR.COM/V13/13A11J.pdf> DOI: 10.14456/ITJEMAST.2022.220

# 1 Introduction

In the structure of diseases of the pelvic organs, purulent-inflammatory diseases of the female genital organs in combination with benign hyperplastic diseases of the uterus are in the first place. Uterine fibroids are benign encapsulated tumors with clear boundaries originating from myometrial cells [1].

Adenomyosis is a benign disease of the uterus with a clear localization, developing as a result of endometrial hyperplasia and its germination into nearby muscle fibers is a type of endometriosis [2].

Purulent-inflammatory diseases of the female genital organs are a clinical syndrome characterized by an infectious lesion of the upper parts of the reproductive tract, including endometritis, parametritis, salpingitis, oophoritis, tuboovarian abscess, pelvioperitonitis and their combinations [3-6].

Risk factors for the development of purulent-inflammatory diseases of the female genital organs include young age up to 25 years, features of sexual behavior (frequent change of sexual partners, lack of mechanical barriers to contraception, etc.), the presence of infectious diseases in the anamnesis, obstetric and gynecological operations and intrauterine diagnostic manipulations [7,8].

The main causative agents of purulent-inflammatory processes of the pelvic organs are *Neisseria gonorrhoeae*, *Chlamydia trachomatis*, *T.H. vaginalis*. When the immunocompetence of the body is violated, conditionally pathogenic microorganisms that are present in low titers in the normal microflora of the vagina and perianal region become pathogens: *Bacteroides* spp., *Peptostreptococcus* spp., *Prevotella* spp., *Escherichia coli*, *Gardnerella vaginalis*, *Streptococcus* spp. and other microorganisms [9,10].

The pathogenesis of the development of the purulent-inflammatory process is based on the penetration of a pathogenic microorganism into the human body, the occurrence of a local inflammatory reaction, while biologically active inflammatory mediators are released, leading to a disorder of microcirculation with exudation and simultaneous stimulation of proliferative processes. The mixed nature of the infection in violation of the barrier mechanisms of protection and anti-infectious immunity contributes to the transition of the disease into a chronic form and activation of autoimmune processes, as well as atypical clinical manifestations, depending on the characteristics of the interaction between different types of pathogens. According to the scientific literature, purulent-inflammatory diseases end in recovery in 3% of cases, in other cases, the process takes a chronic course. At the same time, the risk of infertility, miscarriage, adhesions, chronic pelvic pain, and ectopic pregnancy increases, which significantly worsens the quality of life of women [11].

The study of the etiological aspects of the occurrence of uterine fibroids - the initiator of tumor growth, currently remains not fully understood. However, there are laboratory and clinically confirmed data that an increase in the level of estrogens and progesterone leads to an increase in

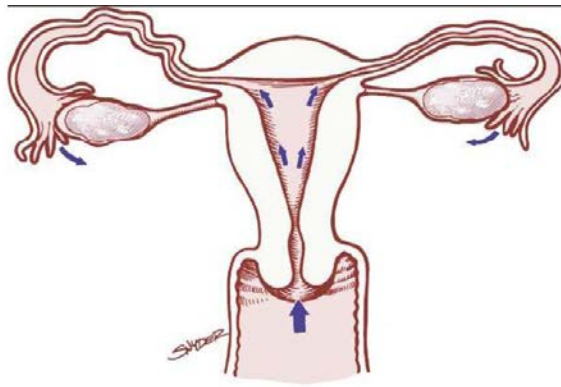
mitotic activity, which can contribute to the formation of fibroids, increasing the likelihood of somatic mutations. In the reproductive period, there are cyclic changes in the level of estrogen and progesterone in the blood, as well as a significant increase during pregnancy and a decrease after menopause [12].

Adenomyosis, or internal endometriosis, is characterized by the appearance of glandular epithelium and cytogenic stroma in the myometrium. It arises from the basal layer of the endometrium. Characteristic morphological features of adenomyosis are the variability of the ratio of glands and stromal component, polymorphism of the glandular component (high, moderate, or low functional activity of glands and cytogenic stroma), and variety of stroma vascularization [13].

In the pathogenesis of the development of the combined pathology of uterine fibroids with adenomyosis, according to some authors, hormonal disorders, inflammatory processes of the female genital organs, and immune disorders lie [14,15]. Morphological studies of tissues in benign hyperplastic diseases of the uterus in most cases reveal signs of a chronic inflammatory process that is associated with infection. Infectious pathogens (viruses, bacteria, and various microorganisms) can cause tumor growth. The chronic inflammatory process can develop against the background of reduced immunity from conditionally pathogenic microorganisms. According to a number of studies conducted, one of the main pathogenesis factors contributing to the penetration of opportunistic microorganisms into the focus of inflammation is systemic and local immunity. It is known that prolonged persistence of microorganisms can lead to the induction of autoimmune reactions in the body, the development of secondary immunodeficiency, and immunosuppression. Thus, pathogenic microorganisms infect the tissues of the myometrium and endometrium, aggravate the pathological process, and contribute to the suppression of humoral and cellular immunity, which leads to a faster progression of the disease [16].

Clinical manifestations of purulent-inflammatory diseases of the female genital organs have a classification described by Baryaeva et al. (2019). According to the presence of complications: uncomplicated - acute salpingitis, endometritis, metroendometritis; complicated - pyosalpinx, piovar, parametritis, tuboovarial abscess, abscess of the rectal uterine space, pelvioperitonitis, peritonitis, sepsis. By localization: one-sided, two-sided. According to the clinical course: acute – with pronounced clinical symptoms (less than 30 days) and chronic – with an unspecified prescription of the disease or a prescription of more than 30 days [17].

The main symptoms of the purulent-inflammatory process of the female genital organs (Fig.1) include abdominal pain, dyspareunia, dysmenorrhea, mucopurulent discharge from the cervical canal or from the vagina in combination with acute cervicitis, bacterial vaginosis or endometritis, abnormal uterine bleeding by the type of intermenstrual spotting, heavy menstruation, postcoital bleeding, more often associated with cervicitis and endometritis [18].



**Figure 1:** Ascending path of infection in the uterus

The symptoms of the disease may be nonspecific and manifest as a general intoxication of the body (fever or chills, dysuria, vomiting). In rare cases, there are no clinical symptoms or atypical symptoms are noted: pain in the right hypochondrium, which may be a consequence of perigepatitis (Fitz-Hugh-Curtis syndrome) [19], which is often the result of chlamydia infection (the causative agent of *Chlamydia trachomatis*).

## 2 Literary Review

Timely diagnosis of purulent-inflammatory diseases of the pelvic organs in women of reproductive age contributes to successful and effective treatment. The primary examination of a gynecologist includes the collection of complaints and anamnesis, physical examination, visual and gynecological examination (examination with mirrors, bimanual gynecological examination), and taking swabs from the vagina and cervical canal. Laboratory tests: blood, urine, cytological and histological examination of vaginal smears. Instrumental studies: colposcopy, ultrasound, tissue biopsy, magnetic resonance examination of the pelvic and abdominal organs, computed tomography, hysteroscopy, and diagnostic laparoscopy [20-25]. To improve the diagnosis of purulent-inflammatory diseases of the female genital organs, objective and subjective symptoms are distinguished and combined into presumptive, additional and specific criteria, which are presented in Table 1.

**Table 1:** Diagnostic criteria for purulent-inflammatory diseases of the female genital organs

Presumptive criteria	Additional criteria	Specific criteria
Soreness during palpation of the lower abdomen	Temperature rise of more than 38.0 °C	Endometrial biopsy with pathohistological signs of endometritis
Painful traction of the cervix during bimanual vaginal examination	A large number of white blood cells in the vaginal secret	Detection by ultrasound or MRI of the pelvic organs of thickened, fluid-filled fallopian tubes, a lumped formation in the ovary area in combination with free fluid in the pelvis
Soreness during palpation of the appendage area during bimanual vaginal examination	Increase in ESR	Detection of signs of inflammation of the pelvic organs according to laparoscopy
-	Increasing the level of CRP	-
-	Detection of <i>N. gonorrhoeae</i> or <i>C. trachomatis</i> in the discharge from the cervical canal	-

Treatment of purulent-inflammatory diseases of the female genital organs is divided into general and local treatment, taking into account the pathogen, and depending on complications and concomitant gynecological pathology can be carried out both conservatively and surgically [26]. 25-35% of women of reproductive age have relapses of the disease, so a woman needs to change her life in order to reduce the risk of recurrent diseases [27].

The effect of purulent-inflammatory diseases of the pelvic organs on reproductive function is manifested by various menstrual cycle disorders, infertility, increased risk of ectopic pregnancy, fetal death, fetal infection, premature birth, arbitrary miscarriages at various stages of pregnancy, frozen pregnancy, anembryonia, fetal hypoxia. During childbirth, there are complications such as the untimely outpouring of amniotic fluid, weakness of labor activity, polyhydramnios [28]. In the postpartum period, it is possible to develop postpartum endomyometritis, the appearance of spots, changes in the immune system, as well as complications in other organs and systems.

The problem of inflammatory diseases of the pelvic organs among women is important for the modern world because this pathology ranks first among gynecological diseases and causes reproductive dysfunction in women. The prevalence of uterine fibroids with concomitant adenomyosis among women of reproductive age suggested a pathogenetic relationship of this pathology with purulent-inflammatory diseases of the female genital organs, confirmed by scientific studies.

### 3 Material and Methods

According to a scientific study, 50 birth histories of women with inflammatory diseases of the pelvic organs for the period 2019-2021 were analyzed. The age of the patients in the study group was 18-35 years, among them up to 20 years – 14, from 21-25 years - 25, from 26-30 years - 6, from 31-35 years – 5 women. Rural women made up 66%, and urban women 34%. According to marital status, 86% were registered married, and 14% of patients were not registered married. All 50 women were registered in the antenatal clinic: 41 patients were registered in the first trimester of pregnancy, 9 patients after 12 weeks.

It was known from the anamnesis that in the study group of women, 70% of women had an abortion, and 30% of women denied having an abortion. The analyzed data revealed the presence of one abortion in the anamnesis of 60% of women, and 40% of women had 2 or more abortions.

In the study group of women with inflammatory diseases, 76% of repeat pregnant women prevailed, and 24% of patients were pre-pregnant.

Purulent-inflammatory diseases of the female genital organs are represented by the following nosological forms: adnexitis - 32%, vaginitis - 24%, salpingitis - 22%, endometritis – 14%, vulvitis – 6%, endocervicitis– 2%.

Concomitant gynecological diseases were not detected in 56% of women. Another category of patients had menstrual cycle disorders in 28% of cases, cervical erosion - 6%, uterine fibroids - 4%, endometriosis - 6%.

Extragenital diseases were not detected in 56% of women. Other women had diseases of the urinary system in 22% of cases, abdominal organs - 10%, respiratory system diseases - 8%, and cardiovascular diseases were detected in 4% of patients.

44% of the patients had no complications during pregnancy. Pregnancy complications were manifested by the following conditions: gestosis – 22%, the threat of premature birth – 14%, chronic fetoplacental insufficiency – 12%, premature discharge of amniotic fluid – 4%, intrauterine infection of the fetus – 4%.

According to the analyzed data, in the study group of women, childbirth through the natural birth canal prevailed in 31 patients, the operative method of delivery – in 19 patients. Indications for operative delivery were in all cases relative and combined. The most common cases were age and infertility in the anamnesis - 32%, labor anomalies – 30%, the presence of a narrow pelvis and a large fetus – 24%, gestosis of pregnant women occurred in 10% of cases, high-grade myopia 2%, placenta previa – in 2% of cases.

The assessment of the condition of newborns on the Apgar scale from mothers with purulent-inflammatory pathology corresponded to: 5-6 points - 3 children, 6-6 points - 4, 5-7 points - 8, 6-7 points - 7, 7-8 points - 9, 8-8 points - 8, 8-9 points - 6, 9-9 points - 5 newborns. Complications were found in newborns in the early neonatal period: hypoxia – 18%, prematurity – 14%, fetal infection – 4%, and 64% of newborns were born without pathologies.

Complications in the postpartum period in mothers were manifested by the following pathologies: uterine subinvolution - 2 (4%), nipple cracks in 2 women (4%), exacerbation of chronic pyelonephritis in 1 (2%) woman. In the remaining patients, the postpartum period proceeded without complications. Discharge from the maternity hospital was carried out on 4-5 days in 62% of women, and 38% of women were discharged on 7-9 days.

In the presented work, the following research methods were used: descriptive, scientific – theoretical, statistical, comparative, and analytical [29,30]. Statistical data analysis was carried out using Statistica®10.0 software.

## 4 Result and Discussion

According to the results of the analysis of the outcome of pregnancy, childbirth and the postpartum period in the study group of women with purulent-inflammatory diseases of the female genital organs, some patients had complications caused by the presence of inflammatory diseases. The revealed pregnancy complications (gestosis of pregnant women, the threat of premature birth, chronic fetoplacental insufficiency, premature discharge of amniotic fluid, intrauterine infection of the fetus) corresponded to their gynecological pathology. Gynecological diseases were noted in 44% of cases, among them, uterine fibroids and endometriosis were diagnosed - in 4% and 6% of cases, respectively. Among the extragenital pathology, the most common was the pathology of the urinary system.

The presence of purulent-inflammatory diseases of the pelvic organs complicated the course of labor, which led to 38% of cases to operative delivery, so these 19 women were discharged only

on 7-9 days. Newborns had complications in the early neonatal period in 36% of cases, among them the most common pathological condition is fetal hypoxia (18%). The negative effect of inflammatory diseases in the postpartum period in the mother was noted in the form of various complications (uterine subinvolution, nipple cracks, exacerbation of chronic diseases), which were promptly identified and treated.

The study showed that purulent-inflammatory diseases of the female genital organs contribute to the occurrence of complications during pregnancy, childbirth and the postpartum period, and also have a negative impact not only on the condition of the mother but also on the fetus. Therefore, in order to prevent complications, it is necessary to carry out timely treatment of existing gynecological diseases.

## 5 Conclusion

Currently, the problem of purulent-inflammatory diseases of the pelvic organs among women in the reproductive period remains relevant in obstetric and gynecological practice. Among gynecological diseases, this pathology occupies the first place and is one of the significant factors in the development of reproductive dysfunction. The study showed that purulent-inflammatory diseases of the female genital organs contribute to the occurrence of complications during pregnancy, childbirth and the postpartum period, and also have a negative impact not only on the condition of the mother but also on the fetus.

An increase in the diagnosed cases of benign hyperplastic uterine diseases (uterine fibroids in combination with adenomyosis) among women of reproductive age suggested a pathogenetic relationship of this pathology with purulent-inflammatory diseases of the female genital organs. As a result of a study of the scientific literature, data on morphological changes in tissues in patients with uterine fibroids in combination with adenomyosis, characteristic of the chronic inflammatory process, were revealed. Timely diagnosis and treatment of gynecological diseases is important in the prevention of reproductive function disorders in women.

## 6 Availability of Data and Material


Data can be made available by contacting the corresponding author.

## 7 References

- [1] Salliss ME, Farland LV, Mahnert ND, Herbst-Kralovetz MM. The role of gut and genital microbiota and the estrobolome in endometriosis, infertility and chronic pelvic pain. *Hum Reprod Update*. 2021 Dec 21;28(1):92-131. DOI: 10.1093/humupd/dmab035.
- [2] Navarro R, Poder L, Sun D, Jha P. Endometriosis in pregnancy. *Abdom Radiol (NY)*. 2020 Jun;45(6):1741-1753. DOI: 10.1007/s00261-020-02486-7
- [3] Workowski KA, Bachmann LH, Chan PA, Johnston CM, Muzny CA, Park I, Reno H, Zenilman JM, Bolan GA. Sexually Transmitted Infections Treatment Guidelines, 2021. *MMWR Recomm Rep*. 2021 Jul 23;70(4):1-187. DOI: 10.15585/mmwr.rr7004a1.
- [4] Osipchuk GV, Povetkin SN, Nagdalian AA, Rodin IA, Rodin MI, Ziruk, IV, et al. The Issue of Therapy Postpartum Endometritis in Sows Using Environmentally Friendly Remedies, *Pharmacophore*.

- [5] Raevskaya A I, Belyalova A A, Shevchenko P P, Karpov S M, Mishvelov A E, Simonov A N et al. Cognitive Impairments in A Range of Somatic Diseases Diagnostics, Modern Approach to Therapy . Pharmacophore 2020;11(1):136-41
- [6] Ayivi R, Ibrahim S, Colleran H, Silva R, Williams L, Galanakis C, Fidan H, Tomovska J and Siddiqui SA. COVID-19: human immune response and the influence of food ingredients and active compounds. Bioactive Compounds in Health and Disease. 2021; 4(6), 100.
- [7] Chen C, Song X, Wei W, Zhong H, Dai J, Lan Z, Li F, Yu X, Feng Q, Wang Z, Xie H, Chen X, Zeng C, Wen B, Zeng L, Du H, Tang H, Xu C, Xia Y, Xia H, Yang H, Wang J, Wang J, Madsen L, Brix S, Kristiansen K, Xu X, Li J, Wu R, Jia H. The microbiota continuum along the female reproductive tract and its relation to uterine-related diseases. Nat Commun. 2017 Oct 17;8(1):875. DOI: 10.1038/s41467-017-00901-0.
- [8] Ya S. Shevchenko, Plohova DP, Bulakhova IN, Mishvelov AE, Kubalova ME, Badriev GB, Kh. A. Mildzikhov, Simonov AN, Verevkina MN, Okolelova AI, Povetkin SN. Experience of carrying out magnetic resonance imaging with the use of specialized protocols and programs computer post-processing. Pharmacophore. 2020;11(2):77-81
- [9] Savaris RF, Fuhrich DG, Duarte RV, Franik S, Ross JDC. Antibiotic therapy for pelvic inflammatory disease: an abridged version of a Cochrane systematic review and meta-analysis of randomised controlled trials. Sex Transm Infect. 2019 Feb;95(1):21-27. DOI: 10.1136/sextrans-2018-053693.
- [10] Luneva A V, Lysenko Y A, Gneush A N, Shantyz A Y, Simonov A N, Verevkina M N, et al. Assessment of the Biosafety of Microorganisms and their Joint Composition. Pharmacophore. 2021;12(3):42-8. <https://doi.org/10.51847/M60cnxYHxz>
- [11] Magun E, DeFilippis EM, Noble S, LaSala A, Waksmonski C, D'Alton ME, Haythe J. Cardiovascular Care for Pregnant Women With Cardiovascular Disease. J Am Coll Cardiol. 2020 Nov 3;76(18):2102-2113. DOI: 10.1016/j.jacc.2020.08.071.
- [12] Burney RO, Giudice LC. Pathogenesis and pathophysiology of endometriosis. Fertil Steril. 2012 Sep;98(3):511-9. DOI: 10.1016/j.fertnstert.2012.06.029.
- [13] Alves P, Castro J, Sousa C, Cereija TB, Cerca N. Gardnerella vaginalis outcompetes 29 other bacterial species isolated from patients with bacterial vaginosis, using in an in vitro biofilm formation model. J Infect Dis. 2014 Aug 15;210(4):593-6. DOI: 10.1093/infdis/jiu131.
- [14] Osipchuk G V, Povetkin S N, Simonov A N, Verevkina M N, Karatunov V, Yakovets M G. On the Issue of Non-Hormonal Stimulation of The Reproductive Function of Rams. Pharmacophore 2020;11(2):73-76.
- [15] Králíčková M, Laganà AS, Ghezzi F, Vetvicka V. Endometriosis and risk of ovarian cancer: what do we know? Arch Gynecol Obstet. 2020 Jan;301(1):1-10. DOI: 10.1007/s00404-019-05358-8
- [16] Reichman O, Sobel J. Desquamative inflammatory vaginitis. Best Pract Res Clin Obstet Gynaecol. 2014 Oct;28(7):1042-50. DOI: 10.1016/j.bpobgyn.2014.07.003.
- [17] Baryaeva O. E., Florensov V. V., Burdukova N. V. Inflammatory diseases of the female genital organs : textbook ; FSBEI VO IGMU of the Ministry of Health of Russia, Department of Obstetrics and Gynecology with a course of gynecology of children and adolescents. Irkutsk: IGMU, 2019, 108 p.
- [18] Patel MD, Young SW, Dahiya N. Ultrasound of Pelvic Pain in the Nonpregnant Woman. Radiol Clin North Am. 2019 May;57(3):601-616. DOI: 10.1016/j.rcl.2019.01.010

- [19] Curry A, Williams T, Penny ML. Pelvic Inflammatory Disease: Diagnosis, Management, and Prevention. *Am Fam Physician*. 2019 Sep 15;100(6):357-364.
- [20] Tovlahanova TJH et al. Study of the Effect of the Image Scanning Speed and the Type of Conductive Coating on the Quality of Sem-Micrographs of Oxide Nano Materials for Medical Use. *Ann Med Health Sci Res*. 2021;11:S3:60-64
- [21] Blinov AV, Nagdalian AA, Povetkin SN, Gvozdenko AA, Verevkin MN, Rzhepakovsky IV, Lopteva MS, Maglakelidze DG, Kataeva TS, Blinova AA, Golik AB, Osipchuk GV, Shariati MA. Surface-Oxidized Polymer-Stabilized Silver Nanoparticles as a Covering Component of Suture Materials. *Micromachines*. 2022; 13(7):1105. DOI: 10.3390/mi13071105
- [22] Yasnaya MA, Blinov AV, Blinova AA, Shevchenko IM, Maglakelidze DG, Senkova AO. Determination of optimal modes for measuring the size of colloidal particles by photon-correlation spectroscopy and acoustic spectroscopy. *Physical and Chemical Aspects of the Study of Clusters Nanostructures and Nanomaterials*. 2020;12:232-242
- [23] Dmitry AnatolyevichDomenyuk, Vladimir AlexandrovichZelensky, Igor Vladimirovich Rzhepakovsky, Oksana Ivanovna Anfinogenova, Application of Laboratory and X-Ray Genral Studies un Early Diagnostics of Metabolic Disturbances of Bone Tissue in Children with Autoimmune Diabetes Mellitus , *Entomol Appl Sci Lett*. 2018;5(4):1-12
- [24] Orsaeva AT, Tamrieva LA, Mischvelov AE, Osadchiy SS, Osipchuk GV, Povetkin SN, Simonov AN. Digital clinic “smart ward. *Pharmacophore*. 2020;11(1):142-146
- [25] Mezhidov BS, Belyaeva AA, Kh. S-M. Bimarzaev, Sh. Bektashev A, Shekhshebekova AM, Dzgoeva MG, et al. Prospects for creating 3D models of internal organs based on computer and magnetic resonance imaging images in emergency surgery and resuscitation. *Pharmacophore*. 2021;11(1):8-14
- [26] Çalıkoğlu EO, Bilge Yerli E, Kavuncuoğlu D, Yılmaz S, Koşan Z, Aras A. Use of Family Planning Methods and Influencing Factors Among Women in Erzurum. *Med Sci Monit*. 2018 Jul 19;24:5027-5034. DOI: 10.12659/MSM.908388.
- [27] Practice Committee of the American Society for Reproductive Medicine. Treatment of pelvic pain associated with endometriosis: a committee opinion. *Fertil Steril*. 2014 Apr;101(4):927-35. DOI: 10.1016/j.fertnstert.2014.02.012.
- [28] Bagnall P, Rizzolo D. Bacterial vaginosis: A practical review. *JAAPA*. 2017 Dec;30(12):15-21. DOI: 10.1097/01.JAA.0000526770.60197
- [29] Siddiqui S. A., Ahmad A., Siddiqui A. A. and Chaturvedi P. Stability Analysis of a Cantilever Structure using ANSYS and MATLAB. *2nd International Conference on Intelligent Engineering and Management (ICIEM)*, 2021, 7-12, DOI: 10.1109/ICIEM51511.2021.9445357
- [30] Siddiqui, S.A., Ahmad, A. Implementation of Newton’s Algorithm Using FORTRAN. *SN COMPUT. SCI*. 2020; 1, 348. DOI: 10.1007/s42979-020-00360-3



**Irina Petrovna Mikhailiuk** is a student of Rostov State Medical University, Rostov-on-Don, Russia



**Yuliya Alexandrovna Shandanovina** is a student of Rostov State Medical University, Rostov-on-Don, Russia




**Djamilya Gadjibalaevna Ramazanova** is a student of Dagestan State Medical University, Makhachkala, Republic of Dagestan, Russia



**Anfisa Andreevna Brynza** is a student of Stavropol State Medical University, Stavropol, Russia



**Khadizhat Shakhbanovna Dzhalaeva** is a student of Dagestan State Medical University, Makhachkala, Republic of Dagestan, Russia



**Rukiyat Shamilevna Abdulaeva** is a student of Dagestan State Medical University, Makhachkala, Republic of Dagestan, Russia



**Khapta Masautovna Adasheva** is a student of the Chechen State University named after A.A. Kadyrov, Grozny, Republic of Chechnya, Russia



**Amina Alibekovna Rashidova** is a student of Dagestan State Medical University, Makhachkala, Republic of Dagestan, Russia



**Linda Masudovna Abzailova** is a student of Kabardino-Balkarian State University named after H.M. Berbekov, Nalchik, Republic of Kabardino-Balkaria, Russia



**Elina Kazbek-Sultanovna Katchieva** is a student of Stavropol State Medical University, Stavropol, Russia