

Clear Aligner: Effectiveness, Limitations and Considerations

Pimsiri Kanpittaya¹, Chidsanu Changsiripun¹, Tanan Jaruprakorn¹, Ruangrat Komolpis¹,
Somsak Chengprapakorn¹, Vudhibhong Laoamata¹, Preeya Suwanwitid¹

¹Department of Orthodontics, Faculty of Dentistry, Chulalongkorn University, Bangkok, Thailand

Abstract

Clear aligner has been an alternative appliance in orthodontic treatment to conventional fixed appliances in adult and teen patients. There are advantages in terms of hygiene, comfort and esthetics, however, clinician expertise and patient compliance are critical for satisfactory treatment results. Lower incisor intrusion, mandibular arch expansion and upper molar distalization are the predictable movements with clear aligner while extrusion and rotation are the movements that require auxiliaries and additional technique to reach the designated position. To achieve the best treatment results, clinicians must consider movement limitations, considerations and recommendations for clear aligner therapy.

Keywords : Clear aligner, Effectiveness, Fixed appliance, Orthodontic treatment

Received date:

Revised date:

Accepted date:

Doi:

Correspondence to :

Preeya Suwanwitid, Department of Orthodontics, Faculty of Dentistry, Chulalongkorn University, Henri-Dunant Road, Wangmai, Pathumwan, Bangkok 10330 Thailand. Email : Mino_tosung@hotmail.com Tel: 02-2188930 Fax: 02-2188953

Introduction

Increasing demand for adult orthodontic treatment has resulted in clear aligners gaining popularity as a treatment option. Clear aligners offer a better experience in terms of hygiene, comfort, esthetics, number of visits and duration compared with conventional fixed appliances.¹ Thus, clinicians consider them as an alternative to conventional fixed appliances.

Clear aligner was first used in orthodontics as a tooth positioner by Kesling² in 1946. In 1993, Sheridan³ suggested using a clear aligner with interproximal reduction

to create tooth movement. However, each clear aligner needed to be manually set up to achieve tooth movement until Invisalign was launched in 1998 (System for incrementally moving teeth with clear aligner. Santa Clara, California Align Technology; 1998) using computer-aided design (CAD) and a computer-aided manufacturing (CAM) process known as stereolithography to produce the appliances.

Initially, clear aligner could only be used to correct simple malocclusions.⁴ However, as the company invested in research and development, the limitations of Invisalign

have been reduced by company innovations such as material innovation, various types of attachments, and the amount of movement per aligner, as well as clinicians gaining expertise in using the appliance.

This review summarizes the effectiveness of clear aligners for different types of tooth movement and the clinical limitations of the appliance.

Clear aligner biomechanics

The mechanism of tooth movement using a clear aligner is classified into two systems.⁵ There is the shape driven system (displacement system), where the shape of the plastic aligner is changed incrementally into each upcoming stage of tooth alignment to move each tooth into the designated position (Fig. 1).

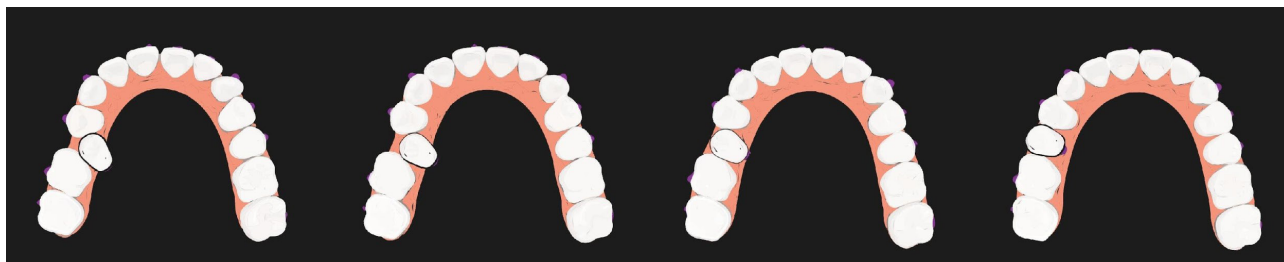


Figure 1 Shape driven system: tooth displacement as changing of aligner's shape

Each tooth is moved based on the plastic aligner's shape. This system can only control simple movements, such as tipping or slight rotation. There is also the force driven system, in which the aligner's plastic is shaped using digital treatment plan software in which the clinician can set the parameters of tooth movement by the aligner combined with other attachments to apply force to the tooth (Fig. 2a., 2b.).

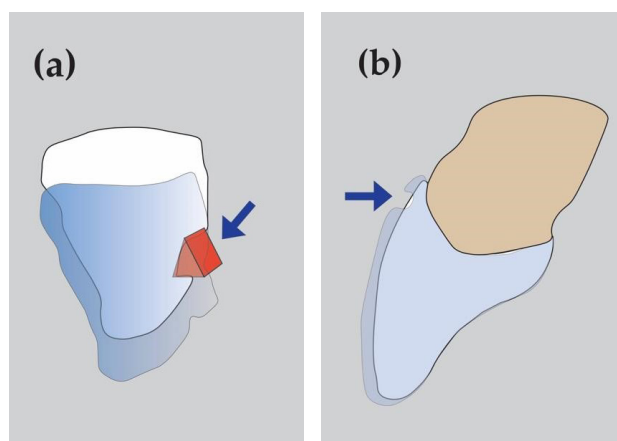


Figure 2 Force driven system : (a) movement from force application: Plastic indentation create force (arrow) to torque root lingually, (b) Force driven system: movement from force application: Tooth extrusion from force (arrow) applied on attachment surface

This system allows for more complicated movement, such as root movement. Biomechanically, aligners produce a pushing force from the plastic to the tooth surfaces or attachments. In contrast, conventional fixed appliances generate a pulling force by ligating the wire and brackets using an elastomeric ring. The predictability of movement with two armamentariums is different because of dissimilar force application concept. Aligners cannot generate a pulling force because they disengage from the tooth. Tipping and intrusion are the most easily accomplished movements for clear aligners.⁶

Plastic is not as rigid as metal wires and brackets so that the aligner may distort when placed on malaligned teeth. Moreover, the plastic edge of the aligner cannot deliver force at the gingival level.⁶ In contrast, force is always applied directly on the occlusal part resulting in intrusion, which is an undesirable movement. Attachments and other auxiliaries are recommended to make specific movements possible. (Fig. 2b.)

Effectiveness of tooth movement

Intrusion/Extrusion

Movement in the vertical plane is challenging when using clear aligners. Kravitz *et al.*⁷ reported a 41 %

accuracy for anterior intrusion and 30 % for extrusion. Khosravi *et al.*⁸ demonstrated good deep bite management with Invisalign appliances; however, the result occurred predominantly due to incisor proclination and relative intrusion, not true intrusion. In contrast, an open bite was successfully treated using incisor extrusion with attachments and posterior intrusion.⁸

A subsequent study⁹ reported a higher accuracy for lower incisors intrusion at 73 %. The improved results could be from a new aligner material called SmartTrack (available after 2013) that the manufacturer claims to give a more gentle and constant force, together with the routine incorporation of overcorrection in the clinicians' digital treatment plan.⁸

To improve the accuracy of vertical movement, the use of horizontal attachments on premolars for retention, bite ramps, or vertical elastics, is recommended. Besides, additional aligners or overbite overcorrection should be used to achieve accurate results.¹⁰

Arch expansion

Two studies demonstrated that maxillary arch expansion using clear aligners occurred via tooth tipping rather than bodily movement^{11,12} with the lowest bodily expansion efficiency found on the maxillary first molar (37 %).¹² The amount of transverse change decreased from anterior to posterior due to multiple factors, such as cortical bone thickness, soft tissue resistance, masticating force, and root anatomy. Moreover, the mechanical efficiency of the force delivered from an aligner decreases from the anterior to posterior region, which might be another concern for effective expansion.¹²

In the mandible, the accuracy of overall arch expansion is 88 %.¹¹ The highest accuracy of bodily movement measurement at the gingival level was found at the premolar and the lowest at the canine. There was no statistical difference between the digital plan prediction and the clinical outcome, which indicated that transverse movement in the mandibular region with clear aligner was predictable.¹¹ However, the authors suggested that the mandible achieved higher accuracy for expansion because

the amount of change required in treatment planning was lower compared to the maxilla.

Crossbite elastics may be used to obtain a better transverse tooth relationship. Overcorrection of maxillary arch expansion is recommended to be prescribed into the digital plan for predictable bodily movement, especially in the posterior region.¹¹ Moreover, appropriate attachments for buccal root torque is important for bodily movement control during arch expansion.

Rotation

Tooth rotation is another challenging movement for clear aligners. Studies demonstrated low accuracy when derotating canines and premolars, 36 % and 40 % respectively, which had round clinical crowns, while higher accuracy was found at the incisors.^{13,14} Interproximal reduction, proper attachment design and staging (amount of movement per aligner) improve rotation accuracy since tooth movement with clear aligner requires sufficient tooth surface area to engage with and enough space with an optimum rate of movement to achieve the predicted rotation.^{13,15} In contrast, in poor compliant patients, attachments in an unfitted aligner may create a counter moment which leads to rotation in the opposite direction. That is the reason why a study showed poor compliance caused a lower mean accuracy of premolar derotation in tooth surface with attachment rather than without attachment.¹³ However attachment selection is a clinician-based decision. For canine derotation, the accuracy of movement is significantly reduced for rotation greater than 15°.¹³ Proper staging for premolar derotation is <1.5° per aligner.⁷

Molar distalization

Molar distalization, translational movement, with clear aligners is predictable. Simon *et al.* reported 87 % accuracy for molar distalization of >1.5 mm on upper molars without using Class II elastics for anchorage.¹³ The accuracy of molar distalization was similar in the attachment-supported group compared with the no attachment group.¹³ These findings agreed with those of another study. Using Class II elastics and attachments, upper first molars could be distalized 2.25 mm without tipping.¹⁶ Class II elastics were

recommended as anchorage preservation during distalization to prevent anterior tooth proclination. Rectangular and vertical attachments were needed on the buccal surface of distalizing molars to create moment resisting undesirable tipping movements.¹⁷

Molar distalization is a common strategy to correct Class II malocclusion without extraction in an adult whose further growth is not anticipated. When using this protocol in hyperdivergent patients, the vertical dimension must be controlled to prevent increasing the lower facial height, which may cause mandibular clockwise rotation and worsen the desired result. Clear aligner is an effective appliance for molar distalization in hyperdivergent patients because there is no significant crown tipping and no significant change in vertical facial height.¹⁶

Premolar extraction site closure

In first premolar extraction cases using clear aligners, tooth movement predictability of upper first molars and upper central incisors were studied. At the maxillary first molars, greater mesial tipping, mesial translation, and intrusion were found than predicted.¹⁸ However, at the central incisors, less retraction, greater lingual crown torque, and extrusion were found than predicted.¹⁸ The predicted tooth move-

ments were not achieved due to anchorage loss. Anchorage tooth preparation was recommended to reach the anticipated tooth movement. Distal crown tipping of the first molars with attachments should be prescribed to maintain the normal angulation and bodily tooth movement.¹⁸ Power ridges, attachments, and greater labial crown torque should be planned in aligner fabrication software to obtain the optimal clinical incisal torque at the end.

The study showed no significant difference in alignment, marginal ridges, occlusal relations, overjet, interproximal contacts, and root angulation in the final result in an extraction case compared with conventional fixed appliances.¹⁹ Although significant differences were found at the occlusal contacts and buccolingual inclination between systems, these were not clinically meaningful. Moreover, good root angulation was well managed with the appropriate attachments. The overall results indicated that with good control, clear aligner is as effective as fixed appliances to treat class I extraction cases.¹⁹

The effectiveness of clear aligner and recommendation for each type of tooth movements are summarized in Table 1.

Table 1 Clear aligner effectiveness and recommendations

	Movement accuracy	Recommendations
Intrusion ⁷⁻¹⁰	- 73% lower incisors intrusion	- SmartTrack material - Overcorrection
Extrusion ⁷⁻¹⁰	- 30% incisor extrusion	- Extrusion attachment
Arch expansion ^{11,12}	- 37% bodily buccal expansion for maxillary first molar - 88% overall mandibular arch expansion	- Preset for sufficient buccal root torque - Overcorrection - Crossbite elastics
Rotation ^{4,13-15}	- 40% premolar rotation - 36% canine rotation	- Interproximal reduction - Attachments - Staging with derotation <1.5° per aligner - Total rotation <15°

Table 1 Clear aligner effectiveness and recommendations (cont.)

	Movement accuracy	Recommendations
Molar distalization ^{11,13,16,17}	- 87% upper molar distalization	- Vertical rectangular attachment on distalized molar with Class II elastics
Premolar extraction site closure ^{18,19}	- No significant difference in alignment, marginal ridges, occlusal relations, overjet, interproximal contacts, and root angulation compared with braces. - Significant difference in occlusal contacts and buccolingual inclination compared with braces.	- Preset with distal tipping of upper first molars - Power ridges, attachment, and greater labial crown torque for incisors

Treatment duration

Treatment with clear aligners occurs more rapidly compared to treatment with fixed appliances.^{20,21} Additional aligners can be prescribed for finishing and detailing the treatment results. Patients who choose clear aligners did so based on esthetics and a shorter treatment time. Many patients rejected extended treatment time to complete difficult tooth movement.²¹ In addition to total treatment duration, clear aligner treatment time is shorter compared with fixed appliances in the number of visits, the number of emergency visits, chairtime per visit, and total chairtime.²² However malocclusion improvement from fixed appliances is better than clear aligner as shown with PAR index (quantitative index to assess an orthodontic outcome).²¹ Pretreatment PAR score of fixed appliances is higher than of clear aligners while post-treatment score is lower which represents the ability of fixed appliances in achieving better clinical results.

Considerations

Clear aligner is an effective alternative for orthodontic treatment. Because it is a removable appliance, patient compliance (proper placement and removal, adequate wearing time) is a crucial factor to achieve the designed tooth movement. Alteration of tooth morphology, such as tooth fracture or new restorations, will result in unfitted aligners thus re-scanning or PVS impression is required. Posterior open bite is a common side effect of clear aligner therapy which is caused by multiple factors that include

anterior interferences due to inadequate anterior intrusion, posterior teeth intrusion from aligner thickness¹⁹, inadequate anterior lingual root torque during anterior retraction, crown tipping during posterior teeth expansion or speedy arch length reduction. Adequate crown torque and anterior intrusion can help prevent a posterior open bite. Posterior vertical elastic or reducing aligner wearing time can simply correct the issue. Tooth movement in a clear aligner is limited only inside the plastic frame, if there is not enough space for alignment or if the tooth is moving slower than the aligner's shape, the tooth will be intruded. Therefore, proper staging of tooth movement and space preparation can prevent a posterior open bite from concurrent movement of the tooth and the aligner.

Conclusion

Clear aligner has gained popularity as a treatment option for adult treatment. The studies showed the effectiveness of clear aligner for distalization of upper molar, expansion of lower molar and intrusion of lower incisor. Limitation of movement stated on incisor extrusion, canine derotation, bodily expansion of upper molar and premolar derotation. Effectiveness and limitation were affected by the quality of the aligner material, clinician expertise, clinician-technician communication, the attitude and cooperation of the patient. All of the considerations are important in achieving successful clinical results.

References

1. Miller KB, McGorray SP, Womack R, Quintero JC, Perelmuter M, Gibson J, *et al.* A comparison of treatment impacts between Invisalign aligner and fixed appliance therapy during the first week of treatment. *Am J Orthod Dentofacial Orthop* 2007;131(3):302 e1-9.
2. Kesling HD. Coordinating the predetermined pattern and tooth positioner with conventional treatment. *Am J Orthod Oral Surg* 1946;32:285-93.
3. Sheridan JJ, LeDoux W, McMinn R. Essix retainers: fabrication and supervision for permanent retention. *J Clin Orthod* 1993;27(1):37-45.
4. Chang MJ CC, Chang CY, Lin JSY, Chang CH, Roberts WE. Introduction to Invisalign® Smart Technology: Attachments Design, and Recall-Checks. *J Digital Orthod* 2019;54:80-95.
5. Tamer I, Oztas E, Marsan G. Orthodontic Treatment with Clear Aligners and The Scientific Reality Behind Their Marketing: A Literature Review. *Turk J Orthod* 2019;32(4):241-6.
6. Brezniak N. The clear plastic appliance: a biomechanical point of view. *Angle Orthod* 2008;78(2):381-2.
7. Kravitz ND, Kusnoto B, BeGole E, Obrez A, Agran B. How well does Invisalign work? A prospective clinical study evaluating the efficacy of tooth movement with Invisalign. *Am J Orthod Dentofacial Orthop* 2009;135(1):27-35.
8. Khosravi R, Cohanin B, Hujoel P, Daher S, Neal M, Liu W, *et al.* Management of overbite with the Invisalign appliance. *Am J Orthod Dentofacial Orthop* 2017;151(4):691-9 e2.
9. Glassick A, Joel Gluck A, Kottelman W, Messersmith M. ALIGNER CORNER. *J Clin Orthod* 2017; 51(4):233-9.
10. Krieger E, Seifert H, Saric I, Jung BA, Wehrbein H. Accuracy of Invisalign(R) treatments in the anterior tooth region. First results. *J Orofac Orthop* 2011;72(2):141-9.
11. Houle JP, Piedade L, Todescan R, Jr., Pinheiro FH. The predictability of transverse changes with Invisalign. *Angle Orthod* 2017;87(1):19-24.
12. Zhou N, Guo J. Efficiency of upper arch expansion with the Invisalign system. *Angle Orthod* 2020;90(1):23-30.
13. Simon M, Keilig L, Schwarze J, Jung BA, Bourauel C. Treatment outcome and efficacy of an aligner technique--regarding incisor torque, premolar derotation and molar distalization. *BMC Oral Health* 2014;14:68.
14. Nguyen C, Chen J. Three-Dimensional Superimposition Tool; In: Tuncay O, editor. The Invisalign System. 1st ed. New Malden: Quintessence Publishing; 2006. p. 121-32.
15. Kravitz ND, Kusnoto B, Agran B, Viana G. Influence of attachments and interproximal reduction on the accuracy of canine rotation with Invisalign. A prospective clinical study. *Angle Orthod* 2008; 78(4):682-7.
16. Ravera S, Castroflorio T, Garino F, Daher S, Cugliari G, Deregibus A. Maxillary molar distalization with aligners in adult patients: a multicenter retrospective study. *Prog Orthod* 2016;17:12.
17. Paquette D. Extraction Treatment with Invisalign; In: Tuncay O, editor. The Invisalign System. 1st ed. New Malden: Quintessence Publishing; 2006. p. 195-205.
18. Dai FF, Xu TM, Shu G. Comparison of achieved and predicted tooth movement of maxillary first molars and central incisors: First premolar extraction treatment with Invisalign. *Angle Orthod* 2019;89(5):679-87.
19. Li W, Wang S, Zhang Y. The effectiveness of the Invisalign appliance in extraction cases using the ABO model grading system: a multicenter randomized controlled trial. *Int J Clin Exp Med* 2015; 8(5):8276-82.
20. Lanteri V, Farronato G, Lanteri C, Caravita R, Cossellu G. The efficacy of orthodontic treatments for anterior crowding with Invisalign compared with fixed appliances using the Peer Assessment Rating Index. *Quintessence Int* 2018;49(7):581-7.
21. Gu J, Tang JS, Skulski B, Fields HW, Jr., Beck FM, Firestone AR, *et al.* Evaluation of Invisalign treatment effectiveness and efficiency compared with conventional fixed appliances using the Peer Assessment Rating index. *Am J Orthod Dentofacial Orthop* 2017; 151(2):259-66.
22. Buschang PH, Shaw SG, Ross M, Crosby D, Campbell PM. Comparative time efficiency of aligner therapy and conventional edgewise braces. *Angle Orthod* 2013.