DEVELOPMENT OF THE REPRODUCTIVE SYSTEM AND LOCALIZATION OF EGG-LAYING HORMONE (ELH) IN THE GONAD OF A TROPICAL ABALONE, HALIOTIS ASININA LINNAEUS

MALEE CHANPOO

A THESIS SUBMITTED IN PARTIAL FULFILLMENT
OF THE REQUIREMENTS FOR
THE DEGREE OF MASTER OF SCIENCE (ANATOMY)
FACULTY OF GRADUATE STUDIES
MAHIDOL UNIVERSITY
2000

ISBN 974-663-859-9

Thesis
entitled

DEVELOPMENT OF THE REPRODUCTIVE SYSTEM AND LOCALIZATION OF EGG-LAYING HORMONE (ELH) IN THE GONAD OF A TROPICAL ABALONE, HALIOTIS ASININA LINNAEUS

Malee Chanpoo
Mrs. Malee Chanpoo
Candidate

Chaitip Wanichanon
Assoc.Prof. Chaitip Wanichanon, Ph.D.
Major-Advisor

Prof. Prasert Sobhon, Ph.D.
Co-advisor

M. Kruatrachue
Prof. Maleeya Kruatrachue, Ph.D.
Co-advisor

Prapee Sretarugsa
Assoc.Prof. Prapee Sretarugsa, Ph.D.
Co-advisor

Prof. Liangchai Limlomwongse, Ph.D.
Dean
Faculty of Graduate Studies

Assoc.Prof.Vijittra Lerdkamolkarn,Ph.D.
Chairman
Master of Science Program
in Anatomy, Faculty of Science

Thesis
entitled

DEVELOPMENT OF THE REPRODUCTIVE SYSTEM AND LOCALIZATION OF EGG-LAYING HORMONE (ELH) IN THE GONAD OF A TROPICAL ABALONE, HALIOTIS ASININA LINNAEUS

was submitted to the Faculty of Graduate Studies, Mahidol University for the degree of Master of Science (Anatomy)

on

April 11, 2000

Malee Chanpoo
....
Mrs. Malee Chanpoo
Candidate

Prapee Sretarugsa
....
Assoc.Prof. Prapee Sretarugsa, Ph.D.
Member

Chaitip Wanichanon
....
Assoc.Prof.Chaitip Wanichanon, Ph.D.
Chairman

M. Kruatrachue
....
Prof. Maleeya Kruatrachue, Ph.D.
Member

....
Prof. Prasert Sobhon, Ph.D.
Member

....
Prof. Liangchai Limlomwongse, Ph.D.
Dean
Faculty of Graduate Studies
Mahidol University

Amaret Bhumiratana
....
Prof. Amaret Bhumiratana, Ph.D.
Dean
Faculty of Science
Mahidol University

ACKNOWLEDGEMENT

I would like to express my sincere gratitude and faithfulness to my advisor, Associate Professor Dr. Chaitip Wanichanon for his kindness, encouragement, correction of thesis, guidance in photographic technique, and spending much time throughout the course of this study.

I am gratefully indebted to Professor Dr. Prasert Sobhon for his esteemed advice, encouragement, supervision, and giving me opportunities to do research with liberty.

I am extremely grateful to Associate Professor Dr. Prapee Sretarugsa and Professor Dr. Maleeya Kruatrachue for their valuable suggestions, comments, and corrections of this thesis.

I am also grateful to Dr. Amporn Thongkukiatkul, from Biology Department, Faculty of Science, Burapha University, who guide me the basic light microscopic techniques, Mr. Vichai Linthong for his helpful advice and assistance in electron microscopic techniques.

My deep gratitude and appreciation are extended to the member of electron microscopy and cell biology laboratory for their kindness and advice throughout the course of my study.

I would like to thank Assoc. Professor Peter J. Hanna, School of Biological & Chemical Sciences, Deakin University, Geelong, Australia, for supplying mouse polyclonal antibody against *H. rubra* egg-laying hormone.

I would like to acknowledge the financial support of the Thailand Research Fund (Senior Research Scholar Fellowship to Prof. Dr. Prasert Sobhon) for the research in this thesis.

My thanks also extends to the Coastal Development Center Prachuab Kiri Khan province and Marine Biological Station, Chulalongkorn University, Angsila, Chonburi province, for supplying monthly abalone specimens.

I am also very grateful to my husband, Dr. Piyapan Chanpoo for his love, care, helpful, understanding and encouragement that have enabled me to carry out my study.

Finally, I would like to express my deepest gratitude to the most beloved persons, my parents, without them, my study would have never been successful.

Malee Chanpoo

4036345 SCAN/M : MAJOR : ANATOMY ; M. Sc. (ANATOMY)
KEY WORDS : HALIOTIS ASININA / GAMETOGENESIS / GONAD DEVELOPMENT / EGG-LAYING HORMONE

MALEE CHANPOO : DEVELOPMENT OF THE REPRODUCTIVE SYSTEM AND LOCALIZATION OF EGG-LAYING HORMONE (ELH) IN THE GONAD OF A TROPICAL ABALONE, HALIOTIS ASININA LINNAEUS. THESIS ADVISOR : CHAITIP WANICHANON, Ph.D., PRASERT SOBHON, Ph.D., PRAPEE SRETARUGSA, Ph.D., MALEEYA KRUATRACHUE, Ph.D. 130P. ISBN 974-663-859-9

The aims of this thesis were to classify the germ cells and study the development of gonad and localization of egg-laying hormone in *Haliotis asinina*. The gonadal histology and germ cells were studied by light microscopy using paraffin and semithin methods. Connective tissue frameworks of the gonad consist of the outer and inner gonadal capsules linked by flat sheets of connective tissue called trabeculae. Trabeculae partition the gonad into compartments and each trabecula acts as the axis on which growing germ cells are attached and proliferate to form oogenetic or spermatogenic unit. Each trabecula contains small capillaries in the center, surrounded by muscle cells, collagen fibers intermingled with fibroblasts, and a substantial number of granulated cells which have many processes. Germ cells in oogenetic unit could be classified into six stages according to their histological characteristics: oogonium and five stages of oocytes, *i.e.*, Oc_1 with intense basophilic cytoplasm, Oc_2 with light basophilic cytoplasm and lipid droplets, Oc_3 with a few yolk granules, Oc_4 with increasing number of yolk granules and thin jelly coat, Oc_5 with numerous yolk granules and fully formed jelly coat. Germ cells in spermatogenetic process could be classified according to the appearance of chromatin and the presence or absence of nucleolus into thirteen stages: spermatogonium, five stages of spermatocytes, secondary spermatocyte, four stages of spermatids and two stages of spermatozoa.

Definitive gonad appears to be clearly separated from the hepatopancreas at 2 months. Gonial cells are found at 2 months; early spermatocytes, spermatids and immature spermatozoa appear at 4 months, early oocytes (Oc_1, Oc_2) are later observed at 6 to 7 months. While completely mature spermatozoa could arise in the gonad as early as 7 months; mature oocytes (Oc_4, Oc_5) occur much later at 10 to 11 months. The male animals tend to reach full sexual maturity and start normal reproductive cycle as early as 7 to 8 month, while female animals reach maturity and start reproductive cycle around 11 to 12 months.

Localization of egg-laying hormone (ELH) was performed by immunofluorescence, immunogold with silver enhancement and immunoperoxidase techniques using polyclonal antibody to recombinant abalone egg-laying hormone (aELH) of *H. rubra* as a probe. Anti-aELH exhibits strong bindings, which implies the presence of aELH, to muscle cells and granulated cells within trabeculae and capsules. The cytoplasm of immature oocytes (stages 1, 2, 3) are moderately stained, while that of mature oocytes (stages 4, 5) are only weakly stained. It is possible that, aELH may be synthesized and released by granulated cells. This hormone may act directly on muscle cells to induce their contraction, which cause the expulsion of ripe oocytes or spermatozoa from the gonad. This study will apply to increase the number of abalone.

4036345 SCAN/M : สาขาวิชา : กายวิภาคศาสตร์ ; วท. ม. (กายวิภาคศาสตร์)

มาลี จันทร์ภู่ : การพัฒนาระบบสืบพันธุ์และการหาตำแหน่งการกระจายของฮอร์โมนกระตุ้นการตกไข่ในระบบสืบพันธุ์ของหอยเป๋าฮื้อ, *Haliotis asinina* LINNAEUS (DEVELOPMENT OF THE REPRODUCTIVE SYSTEM AND LOCALIZATION OF EGG-LAYING HORMONE (ELH) IN THE GONAD OF A TROPICAL ABALONE, HALIOTIS ASININA LINNAEUS) คณะกรรมการควบคุมวิทยานิพนธ์: ชัยทิพย์ วนิชานนท์, Ph. D., ประเสริฐ โศภน, Ph. D., ประพีร์ เศรษฐรักษ์, Ph. D., มาลียา เครือตราชู, Ph. D. 130 หน้า. ISBN 974-663-859-9

หอยเป๋าฮื้อ หรือ หอยร้อยรู เป็นหอยทะเลที่มีเพศแยกจากกันอย่างชัดเจน จากการศึกษาจุลกายวิภาคของอวัยวะสืบพันธุ์ และการผลิตเซลล์สืบพันธุ์ของหอยเป๋าฮื้อในระดับจุลทรรศน์ธรรมดาโดยใช้วิธี paraffin และ semithin พบว่า โครงเนื้อเยื่อเกี่ยวพันที่ห่อหุ้มและค้ำจุนอัณฑะและรังไข่ของหอยเป๋าฮื้อประกอบด้วย ถุงหุ้มภายนอก ถุงหุ้มภายในที่กั้นอัณฑะกับรังไข่จาก hepatopancreas และเยื่อเกี่ยวพันที่แทรกจากถุงหุ้มเข้าไปในรังไข่และอัณฑะเป็นแผง trabeculae ภายในแผง trabeculae แต่ละอันมีหลอดเลือดขนาดเล็กอยู่กลางล้อมรอบด้วยเซลล์กล้ามเนื้อ (muscle cell) เซลล์ขนาดเล็กที่มีนิวเคลียสรูปร่างกลมหรือรี กลุ่มเซลล์เหล่านี้อาจเป็นเซลล์ fibroblast และเซลล์ที่มีแกรนูล (granulated cell) กระจายอยู่ทั่วไป ที่แผง trabeculae มีเซลล์สืบพันธุ์ขั้นต้น และขั้นปลายหุ้มอยู่รอบๆ ในรังไข่เซลล์สืบพันธุ์ประกอบด้วย 6 ขั้นคือ oogonium (Og) และ primary oocytes ขั้นที่ I, II, III, IV และ V ซึ่งมีความแตกต่างกันตามปริมาณสารติดสีด่าง หยดไขมัน (lipid droplets) ก้อนไข่แดง (yolk granules) ภายในไซโตปลาสซึม และสารเคลือบเซลล์ (jelly coat) ที่แต่ละเซลล์สร้างขึ้น การจำแนกชั้นของเซลล์สืบพันธุ์ในหอยเพศผู้ ทำได้โดยการใช้ลักษณะของการขดตัวของโครมาตินและการปรากฏหรือการหายไปของนิวคลีโอลัส เซลล์สืบพันธุ์เพศผู้แบ่งออกเป็น 13 ขั้น คือ spermatogonium, primary spermatocytes 5 ขั้น, secondary spermatocyte, spermatids 4 ขั้น และ spermatozoa 2 ขั้น

การศึกษาการพัฒนาของระบบสืบพันธุ์ในหอยอายุต่างๆกันในช่วงเวลา 1 ปี โดยเทคนิคจุลทรรศน์ธรรมดาพบว่า การพัฒนาของระบบสืบพันธุ์เริ่มปรากฏว่ามี gonial cells เกิดขึ้นเมื่อหอยอายุได้ 2 เดือน เซลล์ระยะต่อมาคือ spermatocytes, spermatids และ immature spermatozoa เกิดขึ้นเมื่อหอยอายุได้ 4 เดือน ส่วนoocytes ขั้นที่ I และ II พบเมื่อหอยอายุ 6 ถึง 7 เดือน อัณฑะที่พัฒนาเต็มที่โดยพบว่ามีเซลล์ mature spermatozoa เกิดขึ้นในหอยอายุ 7 ถึง 8 เดือน ในขณะที่รังไข่เริ่มมีการพัฒนาเต็มที่โดยพบว่ามีเซลล์สืบพันธุ์ขั้นปลายคือ oocytes ขั้นที่ IV และ V ในหอยอายุ 10 ถึง 11 เดือน ดังนั้นในทางปฏิบัติหอยเพศผู้อาจจะถูกใช้เป็นพ่อพันธุ์ได้ตั้งแต่อายุ 7 เดือนขึ้นไป ส่วนเพศเมียต้องรอให้มีอายุอย่างน้อย 11 เดือนขึ้นไป

การหาการกระจายของฮอร์โมนกระตุ้นการตกไข่ (ELH) โดยใช้เทคนิค immunofluorescence, immunogold with silver enhancement และ immunoperoxidase โดยใช้แอนติบอดีต่อ ELH แสดงการติดสีเข้มที่ในเซลล์กล้ามเนื้อ และเซลล์ที่มีแกรนูล ซึ่งกระจายอยู่ในแผง trabeculae และถุงหุ้มด้านนอกและด้านใน นอกจากนี้ยังมีการติดสีเข้มในไซโตปลาสซึมของเซลล์ไข่ขั้นที่ I, II และ III และติดสีจางในไข่ขั้นที่ IV และ V ดังนั้นกลุ่มเซลล์ที่มีแกรนูลนี้อาจจะทำหน้าที่สังเคราะห์ฮอร์โมนที่กระตุ้นการตกไข่ โดยฮอร์โมนชนิดนี้จะไปกระตุ้นเซลล์กล้ามเนื้อที่อยู่ในแผง trabeculae และถุงหุ้มด้านนอกและด้านใน ทำให้เกิดการหดตัวและปล่อยเซลล์สืบพันธุ์ออกจากตัวหอย

CONTENTS

LIST OF TABLES

LIST OF FIGURES

LIST OF ABBREVIATIONS

ac = acrosome
aELH = abalone egg-laying hormone
BSA = bovine serum albumin
ca = capillary
DAB = 3, 3´diaminobenzidine tetrahydrochloride
DSc = diplotene spermatocyte
ept = epithelium
et al. = et alli
F = fibroblast
FITC = fluorescein isothiocyanate
Fo = follicular cell
gr = granulated cell
g = gram
H&E = hematoxylin and eosin
HP = hepatopancreas
Icp = inner capsule
IgG = immunoglobulin gamma
jc = jelly coat
LSc = leptotene spermatocyte
M = molar

M = milliliter
MSc = metaphase spermatocyte
mu = muscle cell
Oc$_1$ = stage 1 oocyte
Oc$_2$ = stage 2 oocyte
Oc$_3$ = stage 3 oocyte
Oc$_4$ = stage 4 oocyte
Oc$_5$ = stage 5 oocyte
Ocp = outer capsule
Og = oogonia
PAS = Periodic Acid Schiff
PBS = phosphate buffer saline
PrSc = primary spermatocytes
PSc = pachytene spermatocyte
Sc = spermatocyte
Sg = spermatogonia
SSc = secondary spermatocyte
St$_1$ = spermatid stage 1
St$_2$ = spermatid stage 2
St$_3$ = spermatid stage 3
St$_4$ = spermatid stage 4
Sz$_1$ = spermatozoa stage 1
Sz$_2$ = spermatozoa stage 2
TBS = tris buffer saline

tr = trabeculae

w/v = weight for volume

yg = yolk granules

ZSc = zygotene spermatocyte

CHAPTER I

INTRODUCTION

Abalone are herbivorous marine snails of the genus *Haliotis*. They are considered as primitive gastropods according to their anatomy and development. There are 20 species among of the known 75 living species of abalone, which are relatively large in size with high market value and are thus captured for commercial fishery (1). Worldwide demand for consumption of abalone has risen steadily and the total markets for abalone, centered in Japan and Asian countries, is estimated at an annual retail value of approximately $ 300 – 400 million (2). Abalone are important economic animal in many countries, such as Japan, America, Mexico and Australia where commercial abalone farms are well established.

A number of surveys have been made on species, abundance and distribution of abalone along the coast of Thailand, and three species, namely, *Haliotis asinina*, *Haliotis ovina* and *Haliotis varia* were found (3, 4, 5). These abalone are also distributed generally over the Indo–western Pacific area, especially in coastal reef zone of Southeast Asia (6, 7). The average shell length and body weight of fully grown abalone of the three species are 10 cm and 170 g in *H. asinina*, 8 cm and 65 g in *H. ovina*, and 6 cm and 6 g in *H. varia*. Therefore, among the three species, *H. asinina* has the largest size and the most potential for commercial exploitation because of their maximum proportion of flesh and good taste, and relative abundance in Thai water (8). *H. asinina* is primary found off the eastern coast of the Gulf of Thailand around Chonburi, Rayong and Trad provinces (9, 10).

Since collection from natural habitat is not sufficient for market demand, combined with the escalating price of the abalone, the interest in abalone aquaculture has been stimulated to replace the collection from depleted natural habitat. In 1991, the Coastal Development Center in Rayong province and in 1997, the Aquaculture Development Center in Prachuab Khiri Khan province had been successful in increasing the fecundity of *H. asinina* and the production of larvae by artificial fertilization. However, the rate of induction of artificial spawning had not been enough for commercial fishery (6, 11). Consequently, there is a need for investigation to understand the development of gonad of *H. asinina* and obtain information on the endocrine function that control reproductive system leading to the improvement of aquaculture system of this abalone, *H. asinina.*

CHAPTER II

OBJECTIVES

1. To investigate the gonadal histology and classify cells in gametogenic process and the trabeculae of gonad in adult *H. asinina* of both sexes by light microscopy in order that the data could be used as base lines for comparison with histological changes occurring during the development of the abalone.
2. To study the development of the gonad in order to determine the age when abalone of both sexes reach full sexual maturity during the one year period by observing histological changes and cellular association.
3. To study the distribution of egg-laying hormone (ELH) in the gonad of adult *H. asinina* by using immunofluorescence, immunogold with silver enhancement and immunoperoxidase methods.

CHAPTER III

LITERATURE REVIEW

Concerning marine snails, members of the Prosobranchia are the largest of the three gastropods subclasses. Abalone are univalve marine gastropods, which are classified in the Phylum Mollusca, Class Gastropoda, Subclass Prosobranchia, Order Archeogastropoda, Suborder Zygobranchia, Superfamily Pleurotomariacea, Family Haliotidae, Genus *Haliotis* (12). The characteristics of the shell such as color, texture, shape, the number of respiratory pores, color of the epipodium and tentacles are often used to distinguish the different abalone species (13).

There are now approximately 75 living species of abalone living on the coasts of every continent of the world (1, 14). The size and distribution of abalone are temperature-dependent; generally abalone inhabitating the temperate and semitropical regions must have a larger size than those in the tropical and arctic regions (15, 16). The red abalone, *Haliotis rufescens*, is the largest abalone in the world; it may attain a length of 30 cm. It is found in the temperate coast of North America (17). The blacklip abalone, *Haliotis rubra*, is about 14 cm in length; it is found in the warm water along the east coast of the Australian Continent. The ezo abalone, *Haliotis discus hannai*, which is in the cooler water off Japan, and the small abalone, *Haliotis diversicolor*, with the length about 5 cm, are found in the tropical region along the coast of Taiwan (14, 18, 19).

The principal producers of abalone are Mexico (34% of world production), Japan (29%), Australia (20%), South Africa (6%), the United States (5%), Korea (2%) and

New Zealand (3%) (2). The product purchased in fresh, frozen, canned, and dried form, is sliced and cooked with other foods. The shells of several species, which are used for decorative purpose, jewelry, and as a traditional medicine in Asia, also have a high market value.

H. asinina have the best potential for commercial culture because of common distribution in Thai water. The interest in abalone, *H. asinina*, culture began in 1989 when the Eastern Marine Fisheries Development Center succeeded in abalone culture for the first time in Thailand. Since then, most studies have been done on practical aspects of finding the most optimal aquaculture system, such as spawning pattern and fecundity of *H. asinina* in captivity based on monthly observation of spawning frequency (20). The growth and survival rates of juvenile abalone have also been studied by using the optimal rearing density and different system (35, 36). However, the information concerning the reproductive biology of this abalone, *H. asinina*, are still inadequate.

External Morphology

Abalone, *H. asinina*, has an oval shape and smooth shell which is brownish green in color (18, 30). The average shell length is about 8 cm, the width is about 4 cm and the body weight is about 170 g (8). The head of the abalone is anterior and the apex of the shell spiral is posterior at the right-hand side. There is a row of holes on the left-hand side of the shell for respiration, removal of wastes and release of gamete cells (18).

The foot, pedal muscle, is not completely covered by the shell. Numerous small tentacles or epipodia are observed around the dorsolateral surface of the foot.

Epipodium presumably detects predators and food by touch and taste. The cephalic tentacles carry the snout and the stumpy eye protuberances. The mouth is at the base of the head, which is called oral disc (18, 31). There are radula in the mouth which are used to rasp food (31). The abalone's internal organs are hidden between the shell and the foot (18). When the shell is removed, the visceral organs are revealed. Adductor muscle of the shell is seen as oval white area, which occupies the center of the body. The visceral organs lie mainly on the left and posterior border of pedal muscle (18, 31).

Reproductive Biology

H. asinina are dioecious, with individuals of separate sexes, as are other abalone species. The sex ratio of *H. asinina* is 1 male to 1 female (10). The gonad is developed on the right side of the body. It forms a large cone-shaped appendage, conical organ, which covers the hepatopancreas. It is externally visible by gently opening a space between the shell and the soft body with a finger (8, 31).

The color of the gonad indicates the sex of the abalone. Ripe female has collections of egg that is dark green or brown in color, thus it is difficult to distinguish the gonad from the hepatopancreas. The mature testis is milky white and easily defined. Usually, immature sex glands of either sex are gray (18). There is no genital duct. The genital organ in both sexes are opened through a simple longitudinal slit in the roof of the central part of the right renal organ, which open to the external by the holes on the shell (8, 31, 32).

During the spawning period, the gonad within the conical appendage gradually becomes engorged. Eggs and sperm are expelled to the cavity of the right renal organ through the shell perforation by contraction of the adductor muscle, which compress the gonad against the body (18, 31). Generally, egg and sperm production depends on size and age of the abalone, but it may depend on species. For example, it has been reported that female ezo abalone, *H. discus hannai*, and red abalone, *H. rufescens*, produced more than 10 million eggs at a time whilst an average sized female greenlip abalone, *Haliotis laevigata*, generally sheded about 2 million eggs. The female ormer abalone, *Haliotis tuberculata,* released 1 million eggs at one time (18, 33). The male red abalone, *H. rufescens*, released about 10^{12} sperm in 30 minutes of spawning (34).

The histology of gonad and gametogenic process have been studied mostly in temperate species abalone, such as, *Haliotis diversicolor diversicolor* (21), *H. discus hannai,* in Rebun Island, Hokkaido, Japan (22, 23) and *H. rufescens* (24). Among abalone species found in Thailand, gametogenic cycle has been studied in *H. varia* (25) and *H. ovina* (26, 41). Recently, the gonadal histology and gametogenic process of *H.asinina* have also been studied by Apisawetakan in 1997 and Sobhon in 1999. The cells in oogenetic units could be classified into 6 stages: oogonium and 5 stages of oocytes. The cells in spermatogenic units could be classified into 13 stages: spermatogonium, 5 stages of primary spermatocytes, secondary spermatocyte, 4 stages of spermatids and 2 stages of spermatozoa (27, 28). Furthermore, it has been shown that the gonad of *H. asinina* exhibit 5 phases of histological pattern during the year: proliferative, premature, mature, spawning and spent phases (27, 28, 29).

Development of the Gonad

Morphogenesis of the fertilized egg starts with the first cleavage and passes through the blastula, gastrula, and finally the trochophore stage, which is the most primitive larval form in the Mollusca (18, 37). The larvae at first are tiny and have no shell. The hatched trochophore, veliger larvae are planktonic and most of them float on the surface of the water (8, 18). For abalone, the minimum duration of larval life is about 4 days (38, 39). But larval life would be expected to be much longer for most species of abalone which inhabit cooler temperature water (13). *H. asinina*, the duration of larval life is about 1 to 3 days (8, 11). In this time the larvae search for a favorable settlement place (8, 18). They secrete an early shell and metamorphose to juvenile. About 1 month after fertilization at a shell length of 2 mm, juveniles form the first respiratory pore on the left side of the shell (6, 11).

At first, the abalone is sexually immature, but after a certain time the gonad starts to develop and the abalone becomes sexually mature and the reproductive cycle repeats itself. The duration that most abalone species become mature is about 1 to 3 years (18, 31) such as the first maturation in male *H. tuberculata* occurs at about 2 years old with shell length about 20-40 mm, while the female reaches maturation at about 3-year-old with 40-50 mm in length (40).

The fecundity of various species of abalone differs. The relationship between shell length and fecundity was observed in important abalone species in the world such as *H. rufescens* with shell length 182 mm in female and 111 mm in male; *Haliotis australis* which has shell length of 91 mm in female and about 62 mm in male (30). The mature gonad of *H. asinina* was observed in females at 9 months old with shell length of at least 48.5 mm for the wild broodstock, and 44.0 mm for the hatchery-reared broodstock (20, 61), while the fecundity of male becomes obvious in animals at 7 ½ months old with shell length of at least 31.0 mm (20, 61, 62). However, the development of gonad of *H. asinina* has not been investigated in detail. Hence, in the present study the development of gonad based on detailed gonadal histology was performed by collecting juvenile abalone from 1 to 12 months old.

Localization of Egg-Laying Hormone in the Gonad

The first signs for the occurrence of hormones in mollusks is concerned with the endocrine control of reproductive activity. Hormones are produced by both neurosecretory cells and non-nervous cells usually grouped together into endocrine organs. Neurosecretory cells are found in large numbers and variety in the molluscan ganglia, and are the principal source of hormone (42). The presence of neurosecretory cell was first demonstrated in mollusks by Scharrer in 1935 (43). Later, Laviolettle (1950) showed that the endocrine played an important part in the control of reproduction by implantation of pieces of gonad in a number of immature slugs, particularly *Arion subfuscus*, brought about a rapid maturation of the gonad glands and ducts which .resulted in oviposition (44). By now neurohormone control of reproduction activity of gastropods and cephalopods have been studied in much details.

A number of gastropod species have been studied with respect to the effects of hormones on their reproductive activities. In *Aplysia californica*, an opisthobranch, egg laying was caused by the extract of bag cells of abdominal ganglion (45, 46). Administration extracts of caudo-dorsal cells (CDC) of cerebral ganglia in *Lymnaea stagnalis*, a pulmonate, also caused egg-laying (47). Among prosobranchs, extracts of several central ganglia have been shown to induce laying of egg capsules in *Busycon canaliculatum* and *Busycon carica* (48, 49). In *Haliotis*, injections of crude homogenates of pleuropedal and visceral ganglia could induce spawning in *H. discus hannai* (50). The peptides that activated egg-laying in *Aplysia* spp. had been characterized and called egg-laying hormone (ELH) (51), whereas it was called caudo-dorsal cell hormone (CDCH) in *L.stagnalis* (52), and abalone egg-laying hormone (aELH) in *H. rubra* (53). These egg-laying hormones may be related, judging from their amino acid numbers and compositions (51, 52, 53).

In pulmonate, injections of intercerebral commissure extracts of *L. stagnalis*, *L. palustris* and *L. ovata* induced ovipositions both isospecifically and heterospecifically, but heterospecifically injections between *Lymnaea* species (subfamily Lymnaeidae) and *Bulinus truncatus* (subfamily Bulinidae) and *Biomphalria glabrata* (subfamily Planorbidae) did not induce oviposition (54).

In opisthobranch, injections of neural extracts from *Aplysia juliana* (subfamily Aplysiinae), *Stylocheilus longicauda* (subfamily Notarchinae) and *Dolabrifera dolabrifera* (subfamily Dolabriferinae), all of which were anaspideans, caused egg-laying between each other (55). The administration of synthetic ELH from *A. californica* also caused egg-laying in *S. longicauda* (56). Localization of ELH and CDCH in pulmonate, *L. stagnalis*, and in prosobranchs, *B. canaliculatum* by using immunofluorescence method has shown immunoreactivity of anti-ELH and anti-CDCH in cerebral ganglion of *L. stagnalis* and these immunoreactivity has also been found in the cerebral ganglion of *B. canaliculatum* (57).

Abalone egg-laying hormone (aELH) in *H. rubra* has been shown to induce the spawning of ova upon injection into maturing female abalone (Hanna et al., unpublished observation). It has been suggested that in primitive prosobranchs, neurohormones probably act directly on the target tissues (58, 59). In abalone, it still remains to be studied where this hormone is synthesized and how it is distributed in the reproductive tissue.

Many techniques for inducing spawning have been developed for Japanese abalone species, namely, *H. discus hannai.* These include the use of exogenous factors such as temperature shock and UV irradiation (60). Nevertheless, similar methods tested in *H. asinina* at the Eastern Marine Fisheries Development Center (EMDEC), such as stimulation by UV irradiation and H_2O_2 treated sea water appeared not to be effective in inducing spawning (6). These indicated that there may be some subtle differences in gonad structure and biology among various abalone species which are still needed to be addressed. Among these studies are: 1) the age when the abalone reach full sexual maturity and could be used as broodstock; 2) the possibility of using artificial means to induce spawning when the gonads are fully developed, so that mature gamete cells from both sexes could be obtained simultaneously; and 3) a more natural mean of inducing gonad maturity and release of gamete cells which could be conveniently collected for artificial fertilization.

Therefore, this study will focus on the study of development of reproductive system of *H. asinina* based on histological changes, and the localization of egg–laying hormone (ELH) in the gonad of these abalone by using mouse polyclonal antibody to recombinant aELH of *H. rubra* for immunohistochemical detections. Hence aELH may be one agent that could be used to induce artificial spawning for commercial cultivation and its synthesis and distribution in the reproductive tissue should be known.

CHAPTER IV

MATERIALS AND METHODS

Experimental Animals

Abalone, *H. asinina*, were obtained from the Marine Biological Station, Chulalongkorn University, Angsila, Chonburi province, and the Coastal Aquaculture Development Center, Prachaub Khiri Khun province, Thailand. These animals were reared in a land-based aquaculture system by being kept in concrete tanks, which were well flushed with filtered sea water, and aerated with mechanical air delivery system. They were given appropriate algal food, usually *Gracilaria* spp., *ad libitum,* and supplemented with artificial food, and kept under normal daylight cycle.

For the studies of histology of the gonad and trabeculae, and classification of cells in gametogenic process, and investigation of the distribution of aELH in the gonad, adult abalone were collected from land-based culture system. Samples of gonad were prepared for histological examinations by paraffin and semithin methods, and for detecting the distribution of aELH by immunofluorescence, immunogold with silver enhancement, and immunoperoxidase methods.

Concerning the study on the development of the gonad, 8 to 10 juvenile abalone reared in the closed culture system as mentioned above were collected monthly from the age of 1 to 12 months, and the gonad were processed for light microscopic observations.

Paraffin Method

Abalone were anesthetized in 5% magnesium choride ($MgCl_2$) for one hour, thereafter their shells were removed. The gonads were cut and fixed in Bouin's fixative. Then, they were dehydrated through 70%, 80%, 90%, 95%, and 100% ethyl alcohol for 30 minutes each, cleared by two changes of dioxane before infiltration and embedding in paraffin wax. Blocks of specimens were cut at a thickness of 4 –5 microns, and stained with Harris's hematoxylin and eosin, or Periodic Acid Schiff (PAS) and hematoxylin (87), They were observed and photographed under an Olympus Vanox light microscope (summarized in Chart 1).

Semithin Method

The gonads were dissected out and sliced into very small pieces and fixed in a solution of 4% glutaraldehyde and 2% paraformaldehyde in 0.1 M sodium cacodylate buffer (pH 7.8) at 4 °C for overnight, and followed by washing in 0.1 M sodium cacodylate buffer to remove the fixative. The specimens were then post–fixed in 1% osmium tetroxide in 0.1 M sodium cacodylate buffer for 1 hour at 4 °C, then dehydrated in a graded series of ethanol (50–100%) for 30 minutes each, cleared in two changes of propylene oxide (PO), infiltrated in a mixture of propylene oxide and Araldite 502 resin at the ratio of 2:1 for 1 hour and 1:2 for overnight before embedding in pure Araldite 502 resin. Then they were polymerized at 30 °C, 45 °C and 60 °C for 24, 48 and 48 hours, respectively. Blocks of specimens were sectioned at 1 micron thickness by an ultramicrotome Porter Blum MT-2, and stained with methylene blue and PAS-methylene blue (summarized in Chart 2).

Protocol for PAS-Methylene Blue Staining

The semithin sections were incubated in 1% periodic acid solution for 10 minutes at 65 °C and washed in distilled water. Then they were stained for 25 minutes at 65 °C in Schiff's reagent and washed in distilled water. The sections were counter-stained in 1% methylene blue (in 1% borax in distilled water) at 65 °C for 5 seconds. Finally, they were washed in distilled water, dried on a hot plate and mounted by using an epoxy glue. Examinations of the tissue sections were done under an Olympus light microscope.

Cryo–Embedding Technique

Gonads of adult abalone were immediately embedded in Tissue Freezing Medium (OCT Tissue – Tek, Miles Laboratories Inc., USA), snapped frozen in liquid nitrogen and stored at -70 °C. The samples were sectioned in the frozen state, on a cryostat machine Leicá CM 1800 at -30 °C and the sections were picked up on the gelatin coated slides. The tissue slides were stained with immunofluorescence, immunogold with silver enhancement and immunoperoxidase method.

Polyclonal Antibody

Mouse polyclonal antibody against *H. rubra* egg-laying was supplied from Assoc. Professor Peter J. Hanna, School of Biological & Chemical Sciences, Deakin University, Geelong, Australia.

Immunofluorescence Method

The cryo–sections were fixed with acetone at –10 °C for 10 minutes. After washing with 0.01 M phosphate buffer saline (PBS), pH 7.4, for 5 minutes, the sections were incubated with 0.1% glycine in 0.01 M PBS and 4% BSA in 0.01 M PBS, to block the background, for 30 minutes each. Finally, the sections were incubated for 1 hour with primary antibody which is mouse polyclonal antibody against *H. rubra* egg-laying hormone (dilution 1:20,000), washed 3 times for 5 minutes each. Then the sections were incubated in secondary antibody fluorescine isothiocyanate (FITC) conjugated rabbit anti–mouse IgG (Sigma Bio Sciences) at dilution 1:100 in moist chamber for 30 minutes, and washed 3 times. The slides were mounted with buffered glycerol, sealed with nail polish, observed with a Nikon HB 10101 AF fluorescence microscope (summarized in Chart 3).

Immunogold Method with Silver Enhancement for Light Microscopy

The frozen sections were thawed and air dried at room temperature for 1 hour. Subsequently, the sections were fixed with acetone at –10 °C for 10 minutes, air dried and washed with 0.01 M phosphate buffer saline (PBS), pH 7.4, for 5 minutes. They were pre–incubated with blocking solution (Zymed CO., California, USA) for 10 minutes at room temperature in the moist chamber to reduce non–specific background staining. Then, the sections were covered with primary antibody which is mouse polyclonal antibody against *H. rubra* egg-laying hormone (dilution 1:20,000). They were washed 3 times in 0.01 M PBS and covered with secondary antibody gold–conjugated rabbit anti–mouse IgG (Zymed) for 30 minutes at room temperature. They were washed 3 times in the buffer, and incubated with silver enhancement solution

(Zymed) for 5-10 minutes and monitored the silver deposit with a microscope. The silver enhancement process was stopped by rinsing the sections with distilled water several times before the background began to appear (self–mucleation), mounted in buffered glycerol. (84, 86). The stained sections were examined under a light microscope and photographed with an Olympus Vanox microscope (summarized in Chart 4).

Immunoperoxidase Method

The frozen sections were thawed and air dried at room temperature for 1 hour. The sections were fixed with acetone at –10 °C for 10 minutes, air dried and washed with 0.05 M tris buffer saline (TBS), pH 7.6, for 5 minutes. After blocking endogenous peroxidase with 3% H_2O_2 for 15 minutes and washed 3 times with 0.05 M TBS for 5 minutes each. The sections were overlaid with 0.1% glycine in 0.05 TBS and 4% BSA in 0.05 M TBS, 30 minutes each in moist chamber to block the non–specific binding of the primary antibody on the sections. Then, the slides were covered with primary antibodies, consisting of mouse polyclonal antibody against *H. rubra* egg-laying hormone (dilution 1:10,000) for 1 hour. The control sections were incubated for 1 hour with 0.05 M TBS and washed 3 times, 5 minutes each. After that the sections were incubated with secondary antibody, biotinylated rabbit anti–mouse IgG, with dilution 1:100 for 30 minutes at room temperature and washed 3 times in the same buffer, then covered with combination of Z–avidin and biotinylated peroxidase in the same buffer, with dilution 1:100 for 30 minutes and washed 3 times in the same buffer. Finally the sections were immersed in the substrate solution containing 5 ml of 0.03% (w/v) 3, 3× diaminobenzidine (DAB) plus 17 µl H_2O_2 for 15 minutes. The sections were washed several times with distilled water, mounted in buffered glycerol, covered with cover slip and sealed with the nail polish (85). The stained sections were observed and photographed with an Olympus Vanox microscope (summarized in Chart 5).

Chart 1 : Paraffin Section Method

Live juvenile and adult abalone

↓

Anesthetized in 5% $MgCl_2$ for 1 h

↓

Fixed in Bouin's solution in 0.1 M sodium cacodylate buffer (pH 7.8) for overnight

↓

Dehydrated through increasing concentrations of ethanol

↓

Infiltrated and embedded in paraffin

↓

Sectioned and stained with H&E, PAS-hematoxylin

↓

Observed under light microscope

Chart 2 : Semithin Section Method

Live juvenile and adult abalone

↓

Anesthetized in 5% $MgCl_2$ for 1 h

↓

Fixed in 4% glutaraldehyde and 2% paraformaldehyde in 0.1 M sodium cacodylate buffer (pH 7.8) at 4°C for overnight

↓

Post – fixed in 1% osmium tetroxide in 0.1 M sodium cacodylate buffer for 2 h

↓

Dehydrated through increasing concentrations of ethanol

↓

Infiltrated and embedded in Araldite 502 resin

↓

Semithin sectioned and stained with methylene blue, PAS-methylene blue

↓

Observed under light microscope

Chart 3 : Immunofluorescence Method

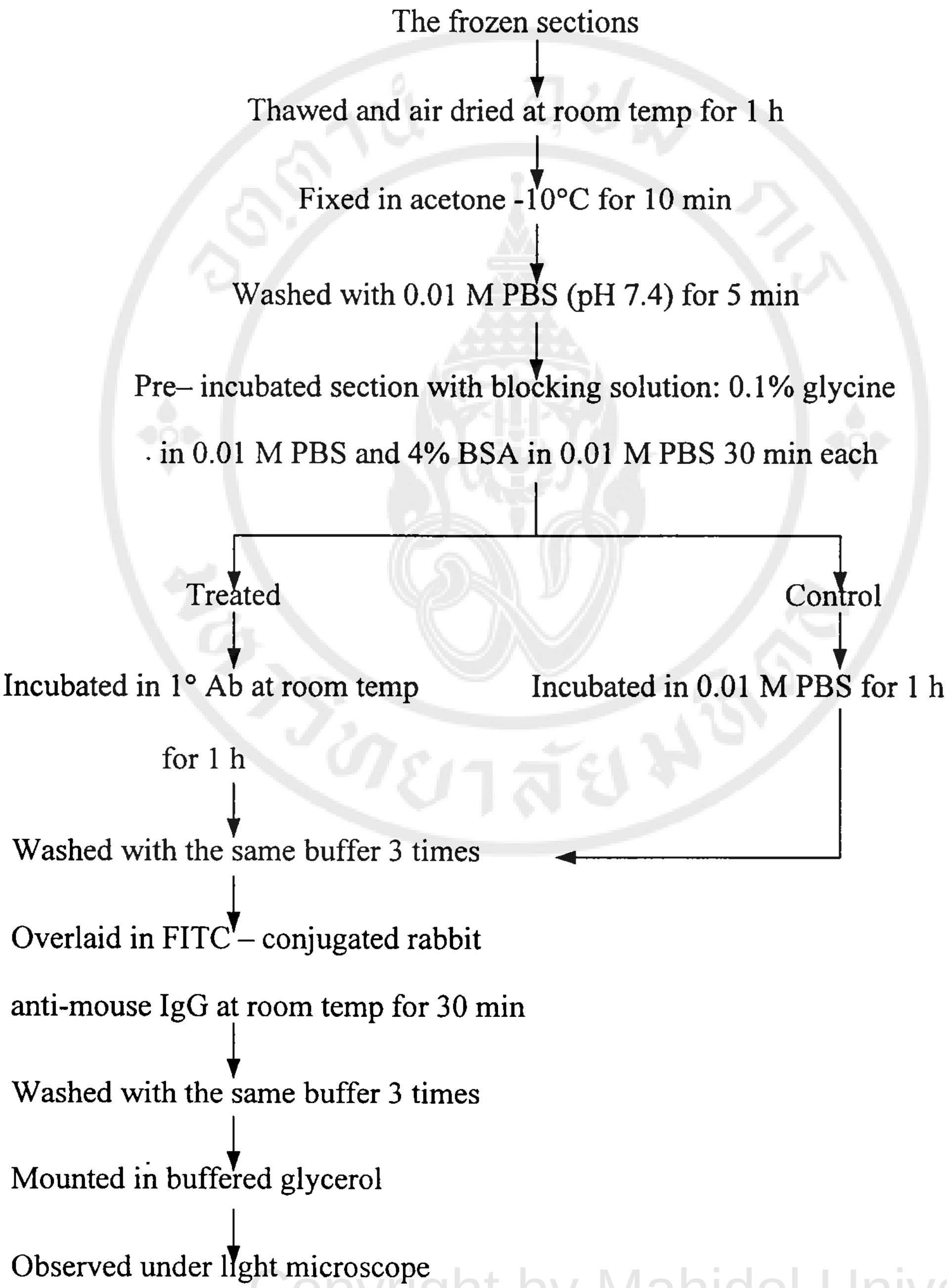

The frozen sections

Thawed and air dried at room temp for 1 h

Fixed in acetone -10°C for 10 min

Washed with 0.01 M PBS (pH 7.4) for 5 min

Pre– incubated section with blocking solution: 0.1% glycine in 0.01 M PBS and 4% BSA in 0.01 M PBS 30 min each

Incubated in 1° Ab at room temp for 1 h

Incubated in 0.01 M PBS for 1 h

Washed with the same buffer 3 times

Overlaid in FITC – conjugated rabbit anti-mouse IgG at room temp for 30 min

Washed with the same buffer 3 times

Mounted in buffered glycerol

Observed under light microscope

Chart 4 : Immunogold Method with Silver Enhancement

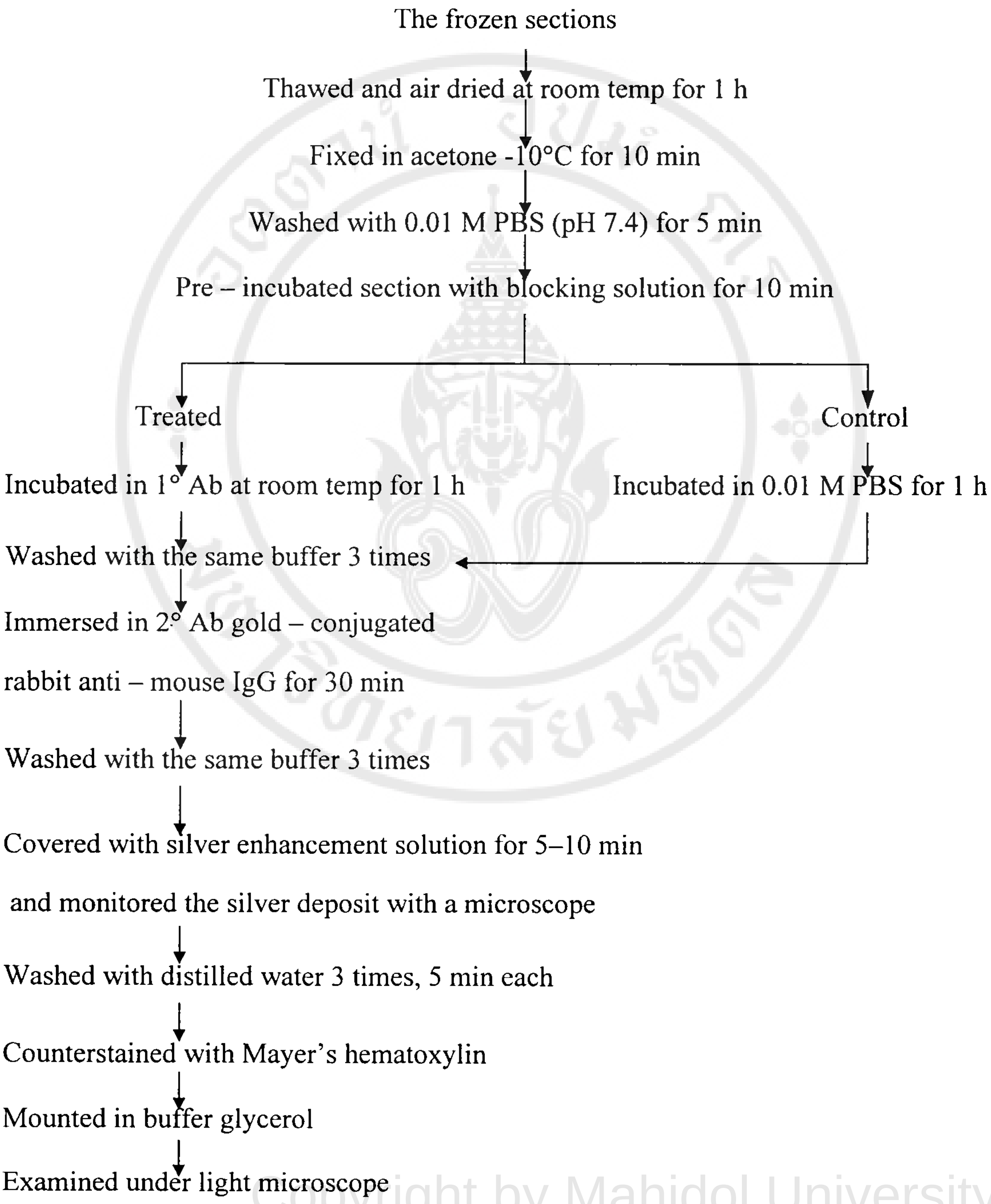

The frozen sections

Thawed and air dried at room temp for 1 h

Fixed in acetone -10°C for 10 min

Washed with 0.01 M PBS (pH 7.4) for 5 min

Pre – incubated section with blocking solution for 10 min

Treated

Incubated in 1° Ab at room temp for 1 h

Control

Incubated in 0.01 M PBS for 1 h

Washed with the same buffer 3 times

Immersed in 2° Ab gold – conjugated rabbit anti – mouse IgG for 30 min

Washed with the same buffer 3 times

Covered with silver enhancement solution for 5–10 min and monitored the silver deposit with a microscope

Washed with distilled water 3 times, 5 min each

Counterstained with Mayer's hematoxylin

Mounted in buffer glycerol

Examined under light microscope

Chart 5 : Immunoperoxidase Method

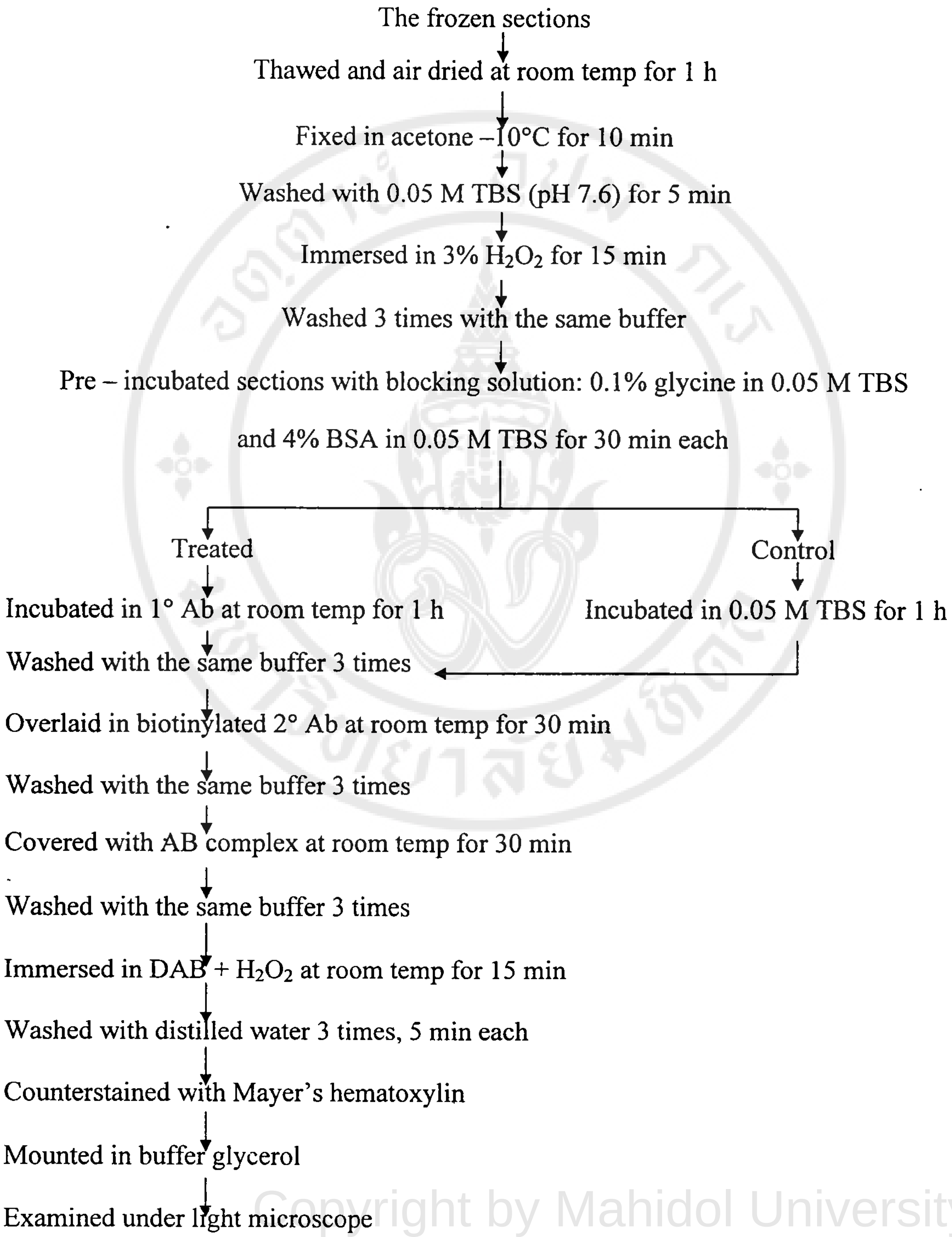

The frozen sections

Thawed and air dried at room temp for 1 h

Fixed in acetone –10°C for 10 min

Washed with 0.05 M TBS (pH 7.6) for 5 min

Immersed in 3% H_2O_2 for 15 min

Washed 3 times with the same buffer

Pre – incubated sections with blocking solution: 0.1% glycine in 0.05 M TBS and 4% BSA in 0.05 M TBS for 30 min each

Treated

Incubated in 1° Ab at room temp for 1 h

Control

Incubated in 0.05 M TBS for 1 h

Washed with the same buffer 3 times

Overlaid in biotinylated 2° Ab at room temp for 30 min

Washed with the same buffer 3 times

Covered with AB complex at room temp for 30 min

Washed with the same buffer 3 times

Immersed in DAB + H_2O_2 at room temp for 15 min

Washed with distilled water 3 times, 5 min each

Counterstained with Mayer's hematoxylin

Mounted in buffer glycerol

Examined under light microscope

CHAPTER V

RESULTS

Gonadal Histology

The conical organ consists of the hepatopancreas surrounded by the testis or ovary (Figs. 1A; 4A). The connective tissue scaffold of the gonad consists of the outer capsule which consists of several layers of alternated muscles and collagen fibers, lined on the outside by a single layer of simple cuboidal epithelium which is PAS positive (Figs. 5B; 6C). On the inside, the connective tissue of the capsule extends inwards to form sheets of loose connective tissue proper called trabeculae, that have straight capillaries running in their cores. Surrounding the capillaries are smooth muscle cells, collagen fibrils, fibroblasts, and granulated cells (Figs. 1D; 3A; 4D; 6A, B; 7). Of special interest in the present study are granulated cells, whose soma are large and have ovoid shape about 10×18 μm in size. Each cell has a small spherical nucleus which contains mostly euchromatin. The cytoplasm contains numerous dense spherical granules about 0.3-0.6 μm in size (Figs. 3B, C, E; 5E; 6B). These cells could give off extensive branches since in many location only cytoplasmic processes containing dense granules were observed (Figs. 3D; 5B; 6C). In PAS stained sections, the granules exhibit PAS-positive substance (Figs. 3C; 4D; 5B; 6B). Generally granulated cells are present in all areas of connective tissue scaffold; however they tend to have higher number in the inner capsules (Figs. 3E; 5E). Trabecular sheets divide gonad into small compartments, and the interior ends of the sheets are connective tissue layers that separate the gonadal from hepatopancreatic tissue.

Each trabecula acts as the axis on which growing germ cells are attached (Figs. 1B, C; 2A, B; 4C; 5A). Early stage cells, such as spermatogonia, initial stages of primary spermatocytes and oogonia, are closely bound to the trabeculae. Middle stage germ cells, such as secondary spermatocytes and developing oocytes, are more detached and appear further away from the trabeculae; while late stage cells, such as spermatids, spermatozoa and mature oocytes are completely detached and move to the outermost region from the axis. Thus, this appearance gives rise to a discrete group of germ cells surrounding each trabecula, which is called the oogenetic or spermatogenic unit.

Classification of Germ Cells

Germ cells in the gonad of *H. asinina* can be classified, according to nuclear characteristics and the cell size as observed by light microscopy of both paraffin and semithin sections.

1. Oogenetic cells

Female germ cells can be classified into 6 stages, oogonium and 5 stages of growing oocytes.

Oogonium (Og) (Figs. 1B, C; 2C; 3A)

Oogonium has a spherical shape, and its size is 8-10 μm in size. The nucleus is round and about 6 μm in diameter. It contains a thin rim of heterochromatin along the nuclear envelope, with the remaining majority appearing as euchromatin. The nucleolus is small and condensed. The cytoplasm is intense basophilia, which is stained light blue by hematoxylin-eosin and methylene blue. The oogonium is attached to the trabeculae and is usually concentrated in groups (Fig. 2C). Each oogonium is surrounded by squamous-shaped follicular cells.

Stage 1 Oocyte (Oc_1) (Figs. 1B, C; 2B, C; 3A)

Stage 1 oocyte has a spherical shape with a diameter of 15-25 μm. The nucleus is about 10 μm in diameter. There are dense chromatin fibers in the nucleus. The nucleolus is present but tends to be obscured by dense nucleoplasm. The cytoplasm is very intense basophilia. Stage 1 oocyte is attached to the trabecula and is surrounded by few follicular cells.

Stage 2 Oocyte (Oc_2) (Figs. 1B, C; 2B; C)

Stage 2 oocyte has columnar shape; its size is around 30×55 μm. The nucleus is round and about 25 μm in diameter. It exhibits moderately decondensed chromatin and the nucleoplasm is transparent so the nucleolus and nuclear membrane boundary are clearly distinct. The cytoplasm is stained light blue similar to the oogonium and contains clusters of lipid droplets (Fig. 2B, C). Each stage 2 oocyte is surrounded by follicular cells and is attached to the trabecula.

Stage 3 Oocyte (Oc_3) (Figs. 1B, C; 2B)

Stage 3 oocyte has a pear shape, with the narrow side attached to the connective tissue trabecula. The cell size is 35-70 μm, and the nucleus is about 25 μm. The nucleus contains chromosomes, which are mostly decondensed into small fibers and the nucleoplasm is quite transparent. The nucleolus is prominent and becomes enlarged due to the uncoiling of its chromatin. The cytoplasm is moderately basophilia and starts to develop reddish yolk granules with increasing lipid droplets. There are fine blue granules distributed between lipid droplets and yolk granules. Several follicular cells surround both the cell membrane and its base near trabecula.

Stage 4 Oocyte (Oc_4) (Figs. 1B, C; 2D)

This cell is tear-drop in shape and is still attached to the trabecula. The cell size is 50-80 μm, and the nuclear size is about 28 μm. The nucleus contains mostly euchromatin and transparent nucleoplasm. The nucleolus is larger in size and is more transparent. The cytoplasm is moderate basophilia and filled with numerous yolk granules and lipid droplets. Fine blue granules are translocated to concentrate as a stripe underneath the cell membrane. A thin layer of jelly coat starts to form on the outer surface of the cell membrane. The jelly coat is positively stained with PAS (Fig. 1C) and it is in turn surrounded by follicular cells.

Stage 5 Oocyte (Oc_5) (Figs. 1B, C, D; 2A, B; 3A)

Stage 5 oocyte is the largest cell with polygonal shape. The cell size is 90-100 μm and the nuclear size is about 50 μm. The nucleus contains chromosome which is completely decondensed. The nucleolus is clear and completely enlarged. The cytoplasm is basophilia and shows numerous lipid droplets and yolk granules. Stage 5 oocyte could be divided into 2 subgroups based on the characteristics of yolk granules. The first subgroup contains small and similar size yolk granules that are scattered evenly throughout the cytoplasm. In the second subgroup, the yolk granules are variable in size, and most are large bodies that could be formed by the coalescence of the smaller yolk granules (Figs. 3D, E). Stripes of fine blue granules are also located underneath the cell membrane as in stage 4 oocyte. The thick jelly coat, which is PAS positive, surrounds the stage 5 oocyte which has no surrounding follicular cells. Stage 5 oocyte is completely detached from the trabecula (Fig. 3D). It is the mature oocyte before being released from the adult female.

2. Spermatogenic cells

Male germ cells can be classified into 13 stages.

Spermatogonium (Sg) (Figs. 4D; 5D)

This cell has a spherical or oval shape with a diameter of 8-10 μm. Its nucleus is round with a diameter of 6-7 μm. The nucleus contains euchromatin with a thin rim of heterochromatin attached to the inner surface of the nuclear envelope. The nucleolus is prominent and the nucleoplasm is transparent. These cells are bounded to the trabeculae.

Primary Spermatocyte (PrSc)

There are 5 stages of primary spermatocyte, *i.e.*, leptotene (LSc), zygotene (ZSc), pachytene (PSc), diplotene (DSc), and metaphase (MSc) stages.

Leptotene Spermatocyte (PrSc) (Figs. 4D; 5D; 6B, C, D)

Leptotene spermatocyte is larger than spermatogonium. It is a round-shaped cell with a diameter of 10-12 μm. The nucleus is large and round with a diameter of 7-8 μm. There is a thin rim of heterochromatin along the nuclear envelope and small blocks of heterochromatin scattered throughout the nucleus. The nucleolus is not as prominent as that in spermatogonium.

Zygotene Spermatocyte (ZSc) (Figs. 4B, D; 5D, E; 6B, C, D)

Zygotene spermatocyte has the same size as leptotene spermatocyte, but there are heterochromatin blocks which are increasing in size and density within the nucleus. The nucleolus of zygotene spermatocyte completely disappears.

Pachytene Spermatocyte (PSc) (Figs. 4B, D; 5D, E; 6B; C)

Pachytene spermatocyte has a round shape with a diameter of about 8 μm; the nuclear diameter is about 5 μm. There are thick fibers of heterchromatin that are entwined into "bouquet pattern".

Diplotene Spermatocyte (DSc) (Figs. 4B, D; 5D; 6B, C)

Diplotene spermatocyte is similar to pachytene spermatocyte, but the nucleus becomes smaller, with a diameter of about 4 μm. The nuclear chromatin is increasingly thicker and more densely packed when compares to that of the pachytene spermatocyte.

Metaphase Spermatocyte (MSc) (Figs. 4D; 6B, C)

This stage exhibits thick chromosomes that move to the equatorial region and the nuclear membrane completely disappears.

Secondary Spermatocyte (SSc) (Figs. 4D; 6C)

Secondary spermatocyte is a small round cell about 7 μm in diameter; the size of the nucleus is about 4 μm. This cell shows thick chromatin blocks that are crisscrossing one another, thus appearing like checker-board.

Spermatid (St)

Spermatids consist of 4 stages, *i.e.*, spermatid stage 1 (St_1), spermatid stage 2 (St_2), spermatid stage 3 (St_3) and spermatid stage 4 (St_4) depending on the size, chromatin granulation and condensation. All stages are round, and ranging in size from 6 μm in spermatid stage 1 to 2-3 μm in spermatid stage 4.

Spermatid stage 1 (St_1) (Figs. 4D; 5D)

Spermatid stage 1 has a round nucleus. This cell can be distinguished by its chromatin which appears as fine granules under LM, that are uniformly spreaded throughout the nucleus. As a result, the whole nucleus appears moderately dense without any intervening transparent area of nucleoplasm.

Spermatid stage 2 (St_2) (Figs. 4D; 5B, E)

Spermatid stage 2 resembles spermatid stage 1 but the nucleus, which remains round, decreases in size and is located eccentrically within the cell.

Spermatid stage 3 (St_3) (Figs. 4B, D; 5E)

The cell becomes smaller and has an oval shape with eccentrically located nucleus. The chromatin is condensed into dark blocks with intervening light area of nucleoplasm.

Spermatid stage 4 (St_4) (Figs. 4B; 5E; 6C)

The cell becomes smallest and has an oval shape. Its chromatin becomes completely condensed, thus the nucleus appears opaque.

Spermatozoa (Sz)

There are 2 stages of spermatozoa.

Spermatozoa stage 1 (Sz_1) (Figs. 4B; 5E).

The immature spermatozoon has an elongated nucleus with completely dense chromatin. There is an acrosome on one side of the ellipsoid nucleus with a short tail.

Spermatozoa stage 2 (Sz_2) (Figs. 4B; 5B, C, E; 6D)

The mature spermatozoon has a fully elongated nucleus with the size about 1×3 μm. The anterior portion of the head is covered by an acrosome (Fig. 5C) and the posterior part is elongated tail.

Both immature and mature sperm are completely detached from the trabeculae and come to lie in row in the space between adjacent spermatogenic units (Figs. 4B, C, D; 5A, C, D; 6A-D).

Development of the Gonad

There is no development of gonad in *H. asinina* at the age of 1 month. The gonad first appears during 2 months. The initial sign is the separation of gonadal capsule (the outer capsule) from the hepatopancreatic capsule (the inner capsule). The outer layer of gonadal capsule is lined by squamous epithelium and the inner layer contains few muscle cells, fibroblasts with bundles of collagen fibrils. Few undifferentiated gonial cells start to appear in the space between the outer and the inner capsule (Figs. 8A-D). The testis of the abalone first appears at the age of 4 months; the testicular tissue covers a quarter of the hepatopancreas. There are Sg, PrSc, SSc and $St_{1\text{-}4}$ lying close to the trabeculae. The outermost part of the spermatogenic unit shows abundant immature spermatozoa whose nuclei are not condensed (Figs. 9A-D). The testis in this period is in late proliferative phase, while the ovary of the same age looks like that of the 2-month-old abalone.

At 6 months, the testis covers almost half of the hepatopancreas. The spermatogenic units are increasing in number. There are Sg, PrSc, SSc, $St_{1\text{-}4}$ and Sz_1 which are more numerous than those at 4 months. The testis at this age is in premature phase (Figs. 10A-D). In female, the ovary is very small and much less developed; the trabeculae starts to form. Few Og, Oc_1 and Oc_2 are attached to the hepatopancreatic capsule (Figs. 11A-D).

At 7 months, the testis is rapidly enlarging and surrounding about half of the hepatopancreas. The spermatogenic units are fully developed. There are various stages of male germ cells, *i.e.*, Sg, PrSc, SSc, $St_{1\text{-}4}$, especially Sz_2 appearing in the space between spermatogenic units. Thus, the testis is in mature phase (Figs. 12A-D). In female, the ovary is still small; the connective tissue trabeculae start to develop and extend from the outer capsule. All oogenetic units are incomplete; there are only Og, Oc_1 and Oc_2 within the ovary, but early stage oocytes are increasing in number. The ovary in this period is in the early proliferative phase (Fig. 13A-D).

At 8 months, the testis is larger than that at 7 months. The testicular tissue covers slightly more than over half of the hepatopancreas. Spermatogenic units are increased in number and containing fully mature male germ cells. In female, the ovary covers about a quarter of the hepatopancreas. The oogenetic unit forms, but it is not yet completed. There are only Og, Oc_1, Oc_2, and few Oc_3 in the ovary. The ovary of this age is in the proliferative phase.

At 9 months, in male, the testis enlarges and almost completely surrounds the hepatopancreas. The mature spermatozoa are increasing in number. The testis is in mature phase, while the ovary is much less developed. The ovarian tissue covers about half of the hepatopancreas. The oogenetic units contain only early stage oocytes (Oc_{1-3}) which are increasing in number. The ovary is in the premature phase.

At 11 months, the testis appears fully developed (Fig. 14A-D). The testicular tissue covers almost all the periphery of the hepatopancreas and is much thickened. There are more numerous spermatogenic units within the testis. In female, the ovary starts to enlarge substantially; the ovarian tissue covers almost all of hepatopancreas. Oogenetic units are completely developed and mature oocytes (Oc_{4-5}) start to appear. Thus, the ovary is in mature phase (Fig. 15A-D).

The male animals tend to reach full sexual maturity and start a normal reproductive cycle as early as 7 to 8 months, while the female animals reach sexual maturity later and start the reproductive cycle around 11 to 12 months (Table 1).

Localization of Egg-Laying Hormone in the Gonad

Immunofluorescence Staining

By using immunofluorescence method, the staining appears to be localized in the capsules of gonad and trabeculae in both sexes and in the cytoplasm of stages 1 and 2 oocytes (Oc_1, Oc_2) of the ovary (Figs. 16B, C, D). Whereas the non-specific fluorescence appears in the jelly coat of the mature oocytes and in spermatocytes (Sc), spermatids (St) and spermatozoa (Sz) of the testis (Figs. 20A; 29A). There are some cells in trabeculae and capsules that are positively stained, but the general fluorescence of the trabeculae is quite strong so that it tends to obscure the positive cells (Figs. 16B, C, D; 20B, C, D; 29B, C, D).

Immunogold Staining with Silver Enhancement

By using immunogold method with silver enhancement, anti-aELH causes strong staining in the granulated cells and muscle cells within the trabeculae and inner capsule of both sexes (Figs. 17C, D; 22C, D; 30C, D). In the proliferative phase of the ovary, the cytoplasm of early stage oocytes (Oc_1, Oc_2, Oc_3) shows moderate staining while the trabeculae and both capsules are weakly stained (Figs. 17C, D). In the mature phase of the ovary, the cytoplasm of late stage oocytes (Oc_4, Oc_5) shows only weakly staining, whereas the trabeculae and both capsules in this phase are moderately stained (Figs. 21B, C, D; 22B, C, D). The trabeculae and both capsules in the mature phase of the ovary show denser staining than those in the proliferative phase (Figs. 17C, D; 21B, C, D; 22B, C, D). The non-specific staining appears in the jelly coat of the mature oocytes (Oc_5) in both treatment and control sections (Figs. 21A-D; 22A, B). However, there is no evidence of staining of spermatocytes, spermatids and spermatozoa (Figs. 30A-D, 31A-D).

Immunoperoxidase Staining

By using immunoperoxidase method, there are strong and specific bindings of anti-aELH in the trabeculae and the capsules of gonad in both sexes. The moderate brownish stain is distinct on the overall content of trabeculae and capsules which delimit gonadal compartments of both ovary and testis (Figs. 18C, D; 24A-D; 25A-D; 27A-D; 28A-D; 32C, D; 34C, D), in contrast to the control sections which are completely unstained (Figs. 18A, B; 23A-D; 26A-D; 32A, B; 34A, B). Within each trabecula, there are more intensely stained spots or streaks, which at high magnification, appear to be muscle cells and granulated cells that contain large brownish granules in the cytoplasm (Figs. 19C, D; 24D; 25D; 27C; 28B, C, D; 33B, D, E; 34D). The latter cells are similar in appearance and general distribution to the granulated cells observed in paraffin and semithin sections, which exhibit better cellular integrity. The positively-stained granulated cells are observed in both the outer and inner capsules and trabeculae. However, there appears to be a higher concentration of these positive cells in the inner capsule that separates gonad from hepatopancreas in both sexes (Figs. 18C, D; 19B, D; 33A). Connective tissue in the trabeculae and capsules are moderately stained, but they appears more intense in the mature phase than that in the proliferative phase of the gonadal cycle (Figs. 18C, D; 19A-D; 24A-D; 25A-D; 27A-D; 28A-D). In the ovary, the cytoplasm of early stage 1 oocytes (Oc_1) is strongly stained, and the cytoplasm of stage 2 and stage 3 oocytes (Oc_2, Oc_3) is moderately stained (Figs. 18C, D; 19A, B, C), while the cytoplasm of stage 4 and stage 5 oocytes (Oc_4, Oc_5) is only weakly stained (Figs. 24B, C; 25A, B, C; 27A, B, D; 28A, B, C). In contrast, there is no positive staining of early male germ cells and spermatozoa in the testis (Figs. 33A, B, C; 34C, D).

Age (month)	General Structure	Gametogenic Unit	Cell Type	Phase of Cycle
2	-Separation of gonadal capsule from hepato-pancreatic (HP) capsule. -Development of few muscle cells in gonadal capsule. -Sexually indistinguishable.	none	only few undifferentiated gonial cells attached to capsules	none
4	-**Male**: testicular tissue covering a quarter of HP capsule. -**Female**: ovary shows no further development. -Sexually distinguishable.	incomplete none	Sg, PrSc, SSc, St_{1-4}, Sz_1 undifferentiated gonail cells	late proliferative none
6	-**Male**: testis covering half of HP capsule. -**Female**: ovary still small and not well developed.	incomplete none	Sg, PrSc, SSc, St_{1-4}, Sz_1 Og, Oc_1, few Oc_2	premature very early proliferative
7	-**Male**: testis covering half of HP capsule. -**Female**: ovary still small.	complete begin to develop from sprouting trabeculae	Sg, PrSc, SSc, St_{1-4}, Sz_{1-2} Og, Oc_1, Oc_2	mature early proliferative
8	-**Male**: testis covering slightly over half of HP capsule. -**Female**: ovary covering about a quarter of HP capsule.	complete incomplete	Sg, PrSc, SSc, St_{1-4}, Sz_{1-2} Og, Oc_1, Oc_2, few Oc_3	mature proliferative
9	-**Male**: testis covering all HP capsule. -**Female**: ovary covering half of HP capsule.	complete incomplete	Sg, PrSc, SSc, St_{1-4}, Sz_{1-2}, Og, Oc_1, Oc_2, Oc_3	mature premature
11	-**Male**: testis covering all HP capsule and much thickened. -**Female**: ovary covering slightly over half of HP capsule.	complete and numerous complete and increasing in number	Sg, PrSc, SSc, St_{1-4}, Sz_{1-2} Og, Oc_1, Oc_2, Oc_3, Oc_4, Oc_5	mature mature

Table I Summary of the key features during the course of development of gonad in ***H. asinina.***

(HP-hepatopancreas; Og-oogonium; Oc-oocyte; Sg-spermatogonium; Sc-spermatocyte;St-spermatid; Sz-spermatozoa)

Method	Capsules				Trabeculae			Oocytes					HP
											Oc_4-Oc_5		
	ept	gr	mu	F/ fibers	gr	mu	F/ fibers	Oc_1	Oc_2	Oc_3	jc	cytoplasm	
Immunofluorescence													
Control	+	-	-	-	-	-	-	-	-	-	+	-	-
Experiment	+	+	+	+	+	+	+	+	+	+	+	+	-
Immunogold with Silver Enhancement													
Control	-	-	-	-	-	-	-	-	-	-	+	-	-
Experiment	+	+	+	+	+	+	+	+	+	+	+	+	-
Immunoperoxidase													
Control	-	-	-	-	-	-	-	-	-	-	-	-	+
Experiment	+	+	+	+	+	+	+	+	+	+	-	+	+

Table II Comparison of immunostaining for ELH in the ovary of ***H. asinina*** by immunofluorescence, immunogold with silver enhancement, and immunoperoxidase methods.

(ept-epithelium; gr-granulated cell; mu-muscle cell; F-fibroblast; Oc-oocyte; jc-jelly coat; HP-hepatopancreas)

Figure 1. Light micrographs of paraffin sections of the ovary stained with H&E in A and B, with PAS in C and D.

A. Low-power micrograph showing hepatopancreas (HP) surrounded by a thin layer of the inner capsule (Icp), and ovarian tissue which is, in turn, surrounded by the outer capsule (Ocp).

B&C. Higher magnifications of the ovary showing each oogenetic unit which consists of an axis of trabecula (tr) surrounded by early stage oocytes (Oc_1, Oc_2, Oc_3). Stage 3 oocytes (Oc_3) show the presence of reddish yolk granules (yg) in the cytoplasm. Late stage oocytes (Oc_4, Oc_5) are surrounded by jelly coat (jc).

D. High-power micrograph of the ovary in Fig C showing two mature oocytes (Oc_5) which are detached from the trabecula. The thick jelly coat (jc) is PAS-positive. A capillary (ca) is present inside the trabecula (tr).

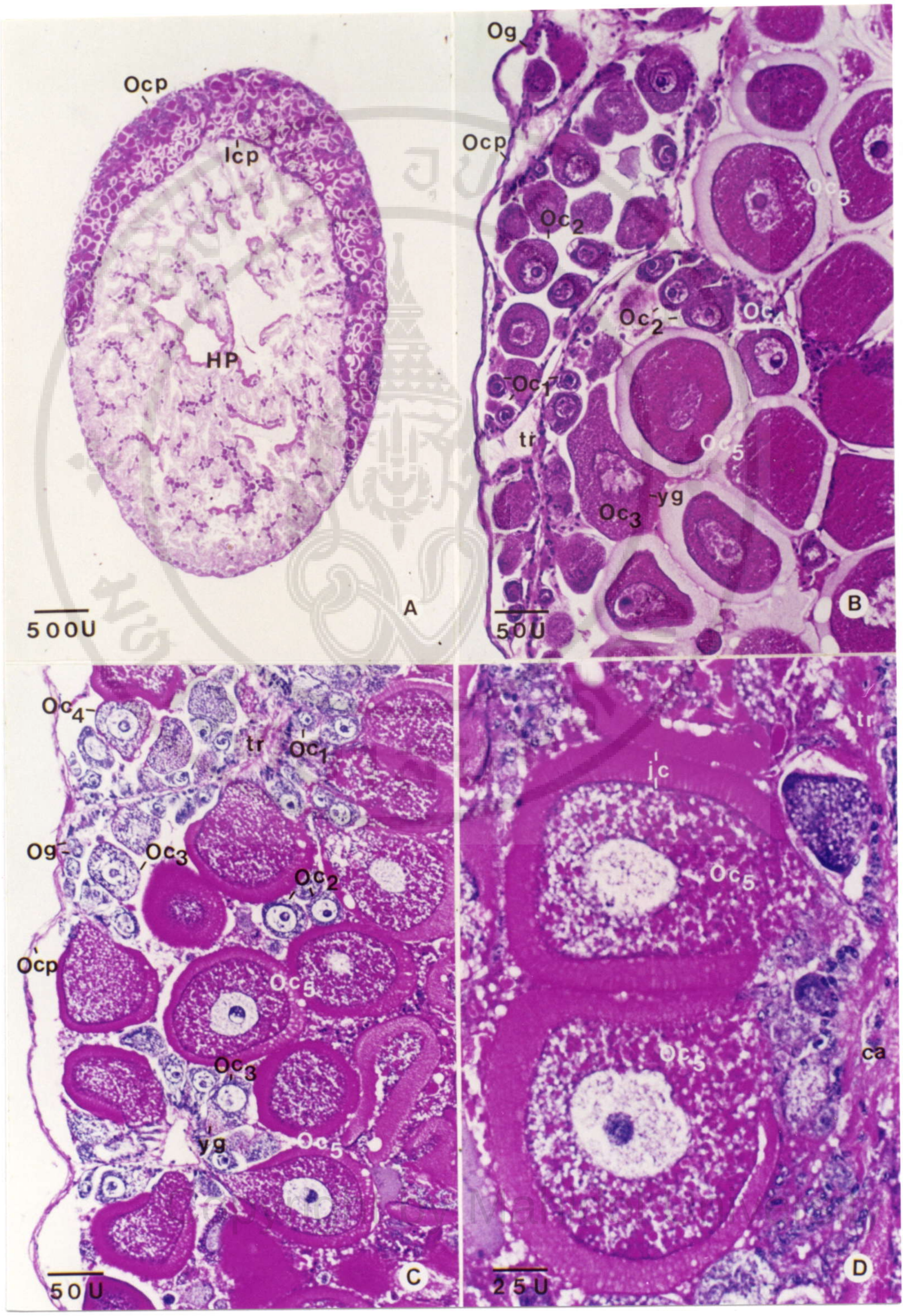
Ocp
Icp
HP
500U
A
Og
Ocp
Oc2
Oc5
Oc2
Oc4
Oc1
tr
Oc5
yg
Oc3
50U
B
Oc4
tr
Oc1
Og
Oc3
Oc2
Ocp
Oc5
Oc3
yg
Oc5
50U
C
tr
jc
Oc5
Oc5
ca
25U
D

Figure 2. Semithin sections of the ovary of *H. asinina.*

A. Low-power micrograph of the ovary stained with PAS showing the outer capsule (Ocp) covering the ovary. The connective tissue trabeculae (tr) extend from the outer capsule into the ovary.

B. High-power micrograph of oogenetic units that consist of all stages of oocytes. Stage 1, 2 and 3 oocytes (Oc_1, Oc_2, Oc_3) lie along and are attached to the connective tissue trabeculae. Stage 5 oocytes (Oc_5), containing numerous of yolk granules and lipid droplets in the cytoplasm, are completely detached from trabeculae.

C&D. High-power micrographs of the ovary stained with methylene blue showing the cluster of oogonia (Og) closely attached to the trabecula. The cytoplasm of stage 1 oocyte (Oc_1) is stained deep blue indicating its intense basophilic property, while the cytoplasm of stage 2 oocyte (Oc_2) is stained light blue and contains cluster of lipid droplets (star). Stage 1 and 2 oocytes are surrounded by follicular cells (Fo). In D, stage 4 oocyte exhibits a large nucleolus and the first appearance of a thin jelly coat (jc) surrounding the cell membrane. The inner capsule (Icp) contains fibroblast (F) and muscle cell (mu).

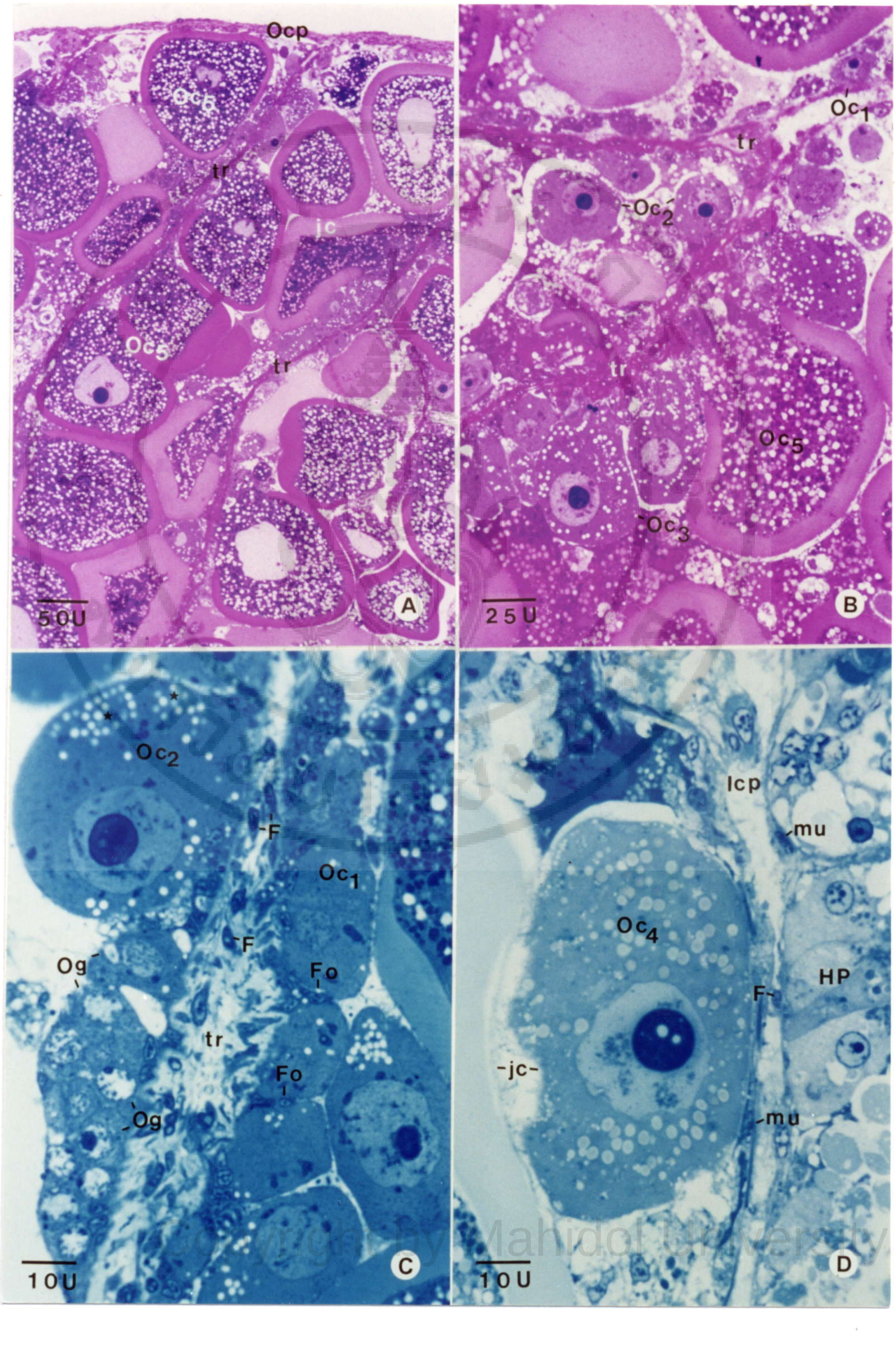
Ocp
Oc_6
tr
jc
Oc_5
tr
50U
A
Oc_1
tr
Oc_2
tr
Oc_5
Oc_3
25U
B
Oc_2
F
Oc_1
F
Og
Fo
tr
Fo
Og
10U
C
lcp
mu
Oc_4
HP
F
jc
mu
10U
D

Figure 3. **A-C.** Photomicrographs of paraffin sections of the mature ovary stained with H&E in A&B, and with PAS in C. In A,the connective tissue from the outer capsule (Ocp) extends into the interior of the gonad to form trabeculae (tr). Each trabecula acts as the axis on which growing germ cells are attached (Og-oogonia, Oc_1-stage 1 oocyte), while mature oocytes (Oc_5-stage 5 oocyte) are detached from the trabecula. In B&C, the connective tissue of the trabecula, and the outer capsule are composed of muscle cells (mu), fibroblasts (F) and PAS-positive granulated cells (gr). **D&E.** Semithin sections of the trabecula, the inner capsule (Icp) and part of a mature oocyte (Oc_5) stained with methylene blue, demonstrating muscle cells (mu), fibroblasts (F), and granulated cells (gr) in the trabecula and the inner capsule. The mature oocyte is surrounded by a thick jelly coat (jc).

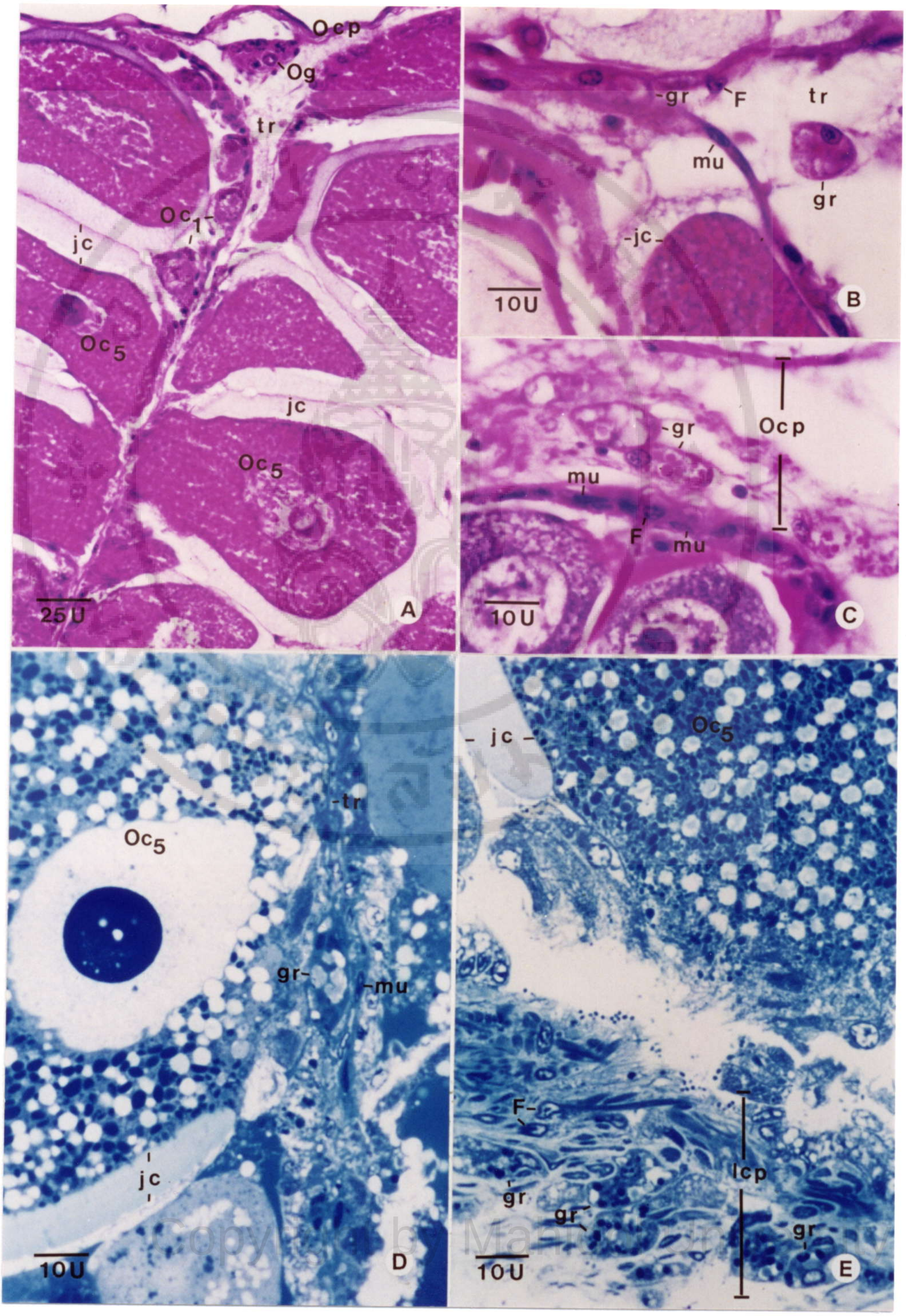
Ocp
Og
tr
Oc1
jc
Oc5
jc
Oc5
25U
A
gr
F
tr
mu
gr
jc
10U
B
Ocp
gr
mu
F
mu
10U
C
tr
Oc5
gr
mu
jc
10U
D
jc
Oc5
F
Icp
gr
gr
gr
10U
E

Figure 4. Light micrographs of paraffin sections of the testis stained with H&E in A and B, and with PAS in C and D.

A. Low-power micrograph showing hepatopancreas (HP) surrounded by a thin layer of the inner capsule (Icp), and testicular tissue which is, in turn, surrounded by the outer capsule (Ocp).

B. High-power micrograph of the testis showing the trabecula surrounded by zygotene spermatocytes (ZSc), pachytene spermatocytes (PSc), diplotene spermatocytes (DSc), spermatid stage 4 (St_4), and spermatozoa (Sz_1, Sz_2).

C. Low-power micrograph showing spermatogenic units which consist of trabeculae and are surrounded by spermatocytes (Sc), spermatids (St) and spermatozoa (Sz)

D. High-power micrograph showing the connective tissue trabecula which is PAS-positive. There are fibroblasts (F), muscle cells (mu) and granulated cells in the trabecula. Lying close to each trabecula are spermatogonia (Sg), leptotene spermatocytes (LSc), zygotene spermatocytes (ZSc), pachytene spermatocytes (PSc), diplotene spermatocytes (DSc), metaphase spermatocytes (MSc), secondary spermatocytes (SSc), and spermatid stage 1, 2 and 3 (St_{1-3}).

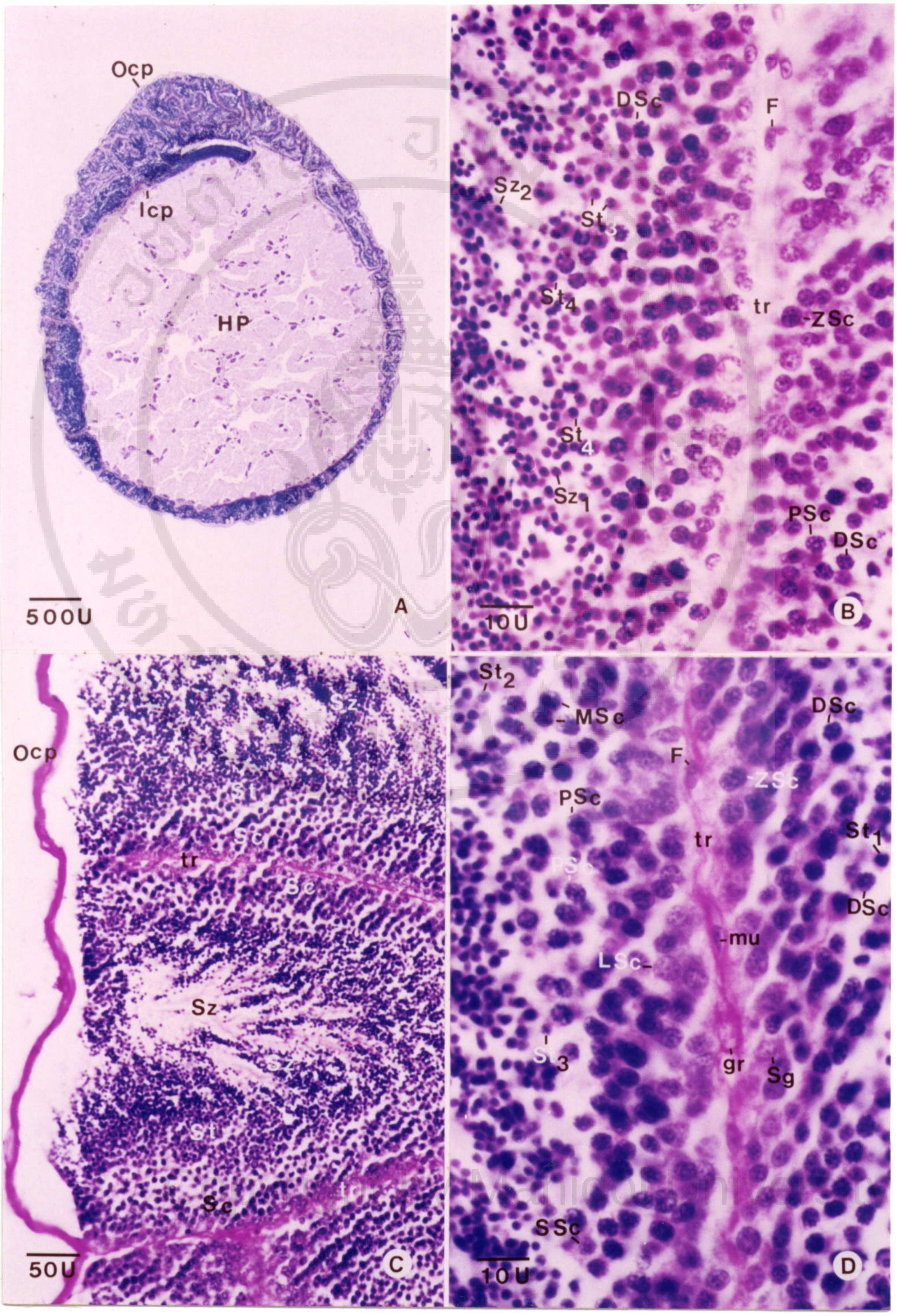
Ocp
Icp
HP
500U
A
DSc
F
Sz2
St3
St4
tr
ZSc
St4
Sz1
PSc
DSc
10U
B
Sz
Ocp
St
Sc
tr
Sc
Sz
Sz
St
Sc
tr
50U
C
St2
MSc
DSc
F
ZSc
PSc
tr
St1
PSc
DSc
mu
LSc
St3
gr
Sg
SSc
10U
D

Figure 5. **A-C.** Semithin sections of the testis stained with PAS-methylene blue showing the outer capsule (Ocp) and spermatogenic unit around each trabecula (tr) in A&B and the accumulation of mature spermatozoa (Sz_2) in gonadal lumen in C (ac-acrosome). In B, note that the outer capsule consists of cuboidal epithelium (ept) with alternate layers of muscle cells (mu) and collagen bundles. Granulated cells and their processes (gr) are present in large number.

D&E. Semithin sections of the testis stained with methylene blue showing cellular components of the trabecula in D and the inner capsule (Icp) in E. Various stages of spermatogonia (Sg), primary spematocytes (LSc-leptotene spermatocyte, ZSc-zygotene spermatocyte, PSc-pachytene spermatocyte, DSc-diplotene spermatocyte), spermatids (St_{1-4}) and spermatozoa (Sz) surround the trabecula (HP-hepatopancreas, mu-muscle cell, F-fibroblast, gr-granulated cell).

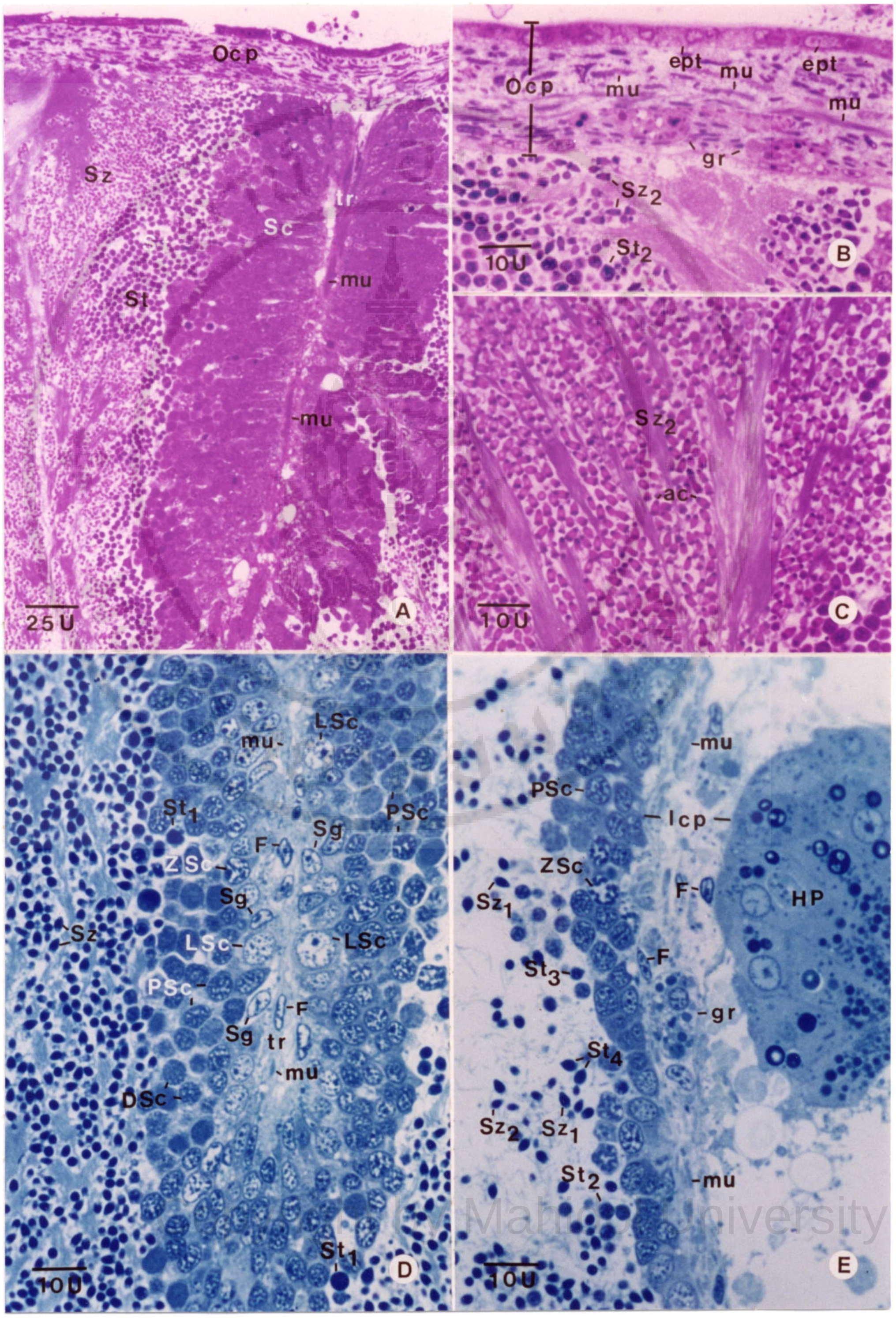
Ocp
Sz
tr
Sc
St
-mu
-mu
25 U
A
Ocp
ept
mu
ept
mu
mu
gr
Sz2
St2
10U
B
Sz2
ac
10U
C
mu
LSc
St1
PSc
Sg
F
ZSc
Sg
Sz
LSc
LSc
PSc
F
Sg
tr
mu
DSc
St1
10U
D
-mu
PSc
Icp
ZSc
F
HP
Sz1
F
St3
gr
St4
Sz2
Sz1
St2
-mu
10U
E

Figure 6. Light micrographs of the testis of *H. asinina* showing the connective tissue trabeculae and spermatogenic units.

A. Paraffin section of the testis stained with H&E showing the trabecula (tr) arising from the outer capsule (Ocp), and small capillary (ca) running in the core of the trabecula.

B. Paraffin section of the testis stained with PAS showing that the interior end of the trabecula is connected with the inner capsule (Icp). There are fibroblasts (F), muscle cells (mu) and granulated cells (gr) in both trabecula and inner capsule.

C. Semithin section stained with methylene blue demonstrating muscle cells (mu) and fibroblasts (F) in the outer capsule (Ocp) and trabecula. Lying close to the trabecula are various stages of male germ cells (LSc-leptotene spermatocyte, ZSc-zygotene spermatocyte, PSc-pachytene spermatocyte, DSc-diplotene spermatocyte, MSc-metaphase spermatocyte, SSc-secondary spermatocyte, St_4-spermatid stage4) and mature spermatozoa (Sz_2).

D. Semithin section stained with PAS-methylene blue showing fibroblasts (F) in the trabecula (tr). The trabecula is surrounded by leptotene spermatocytes (LSc), zygotene spermatocytes (ZSc) and mature spermatozoa (Sz_2).

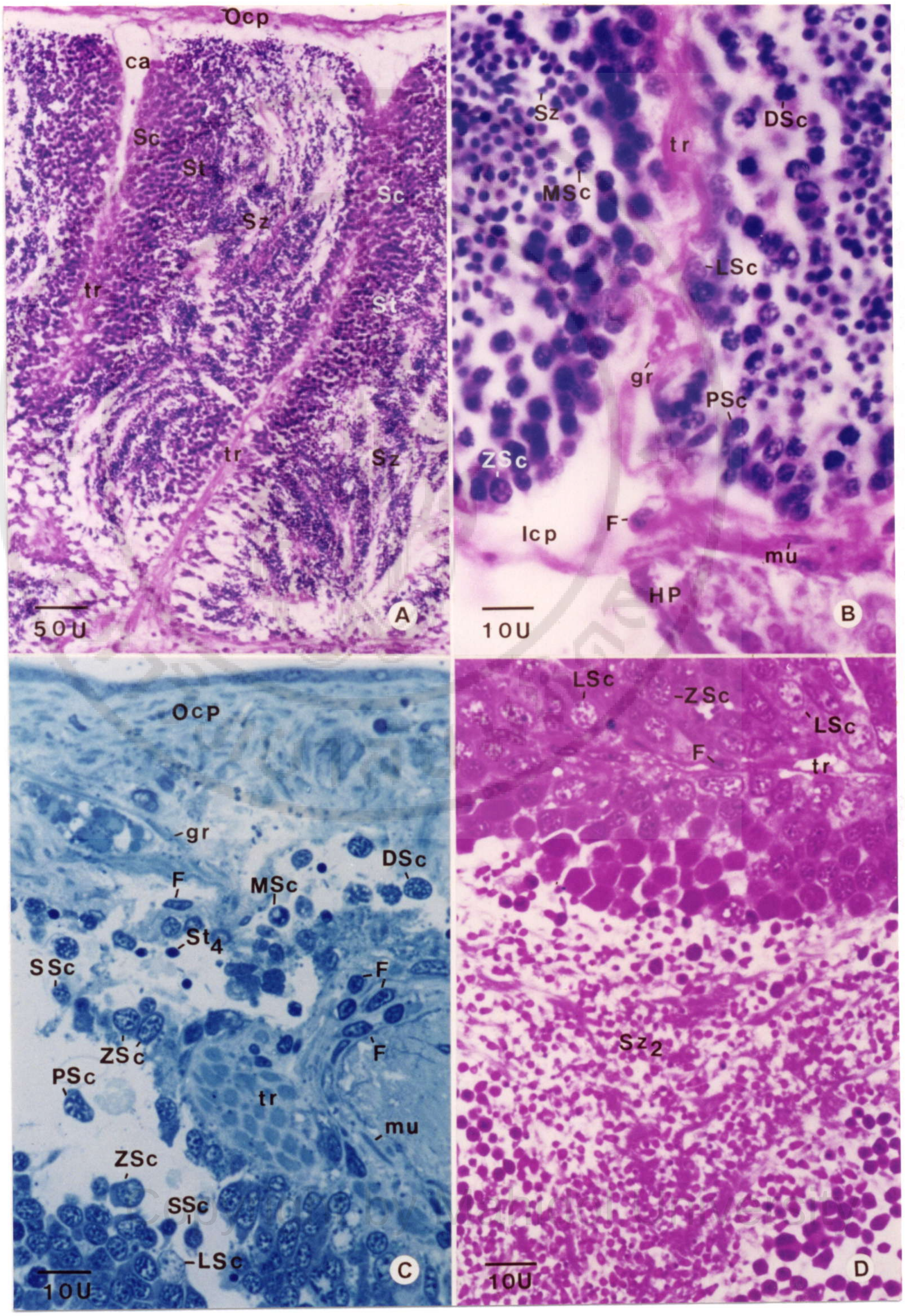
Ocp
ca
Sc
St
Sz
Sc
tr
St
tr
Sz
50U
A
Sz
DSc
tr
MSc
-LSc
gr
PSc
ZSc
Icp
F
mu
HP
10U
B
OcP
-gr
DSc
F
MSc
St_4
SSc
F
F
ZSc
PSc
tr
mu
ZSc
SSc
-LSc
10U
C
LSc
-ZSc
LSc
F
tr
Sz_2
10U
D

Figure 7. A diagram of an oogenetic unit of the ovary of *H. asinina* showing all cell types in the trabecula: fibroblasts (F), muscle cells (mu), and granulated cells (gr). Oogonia (Og) and early stage oocytes (Oc_1, Oc_2, Oc_3) are surrounded by follicular cells (Fo) and closely adhered to the trabeculae. While late stage oocytes (Oc_4, Oc_5) are surrounded by jelly coat (jc) and detached from the trabeculae.

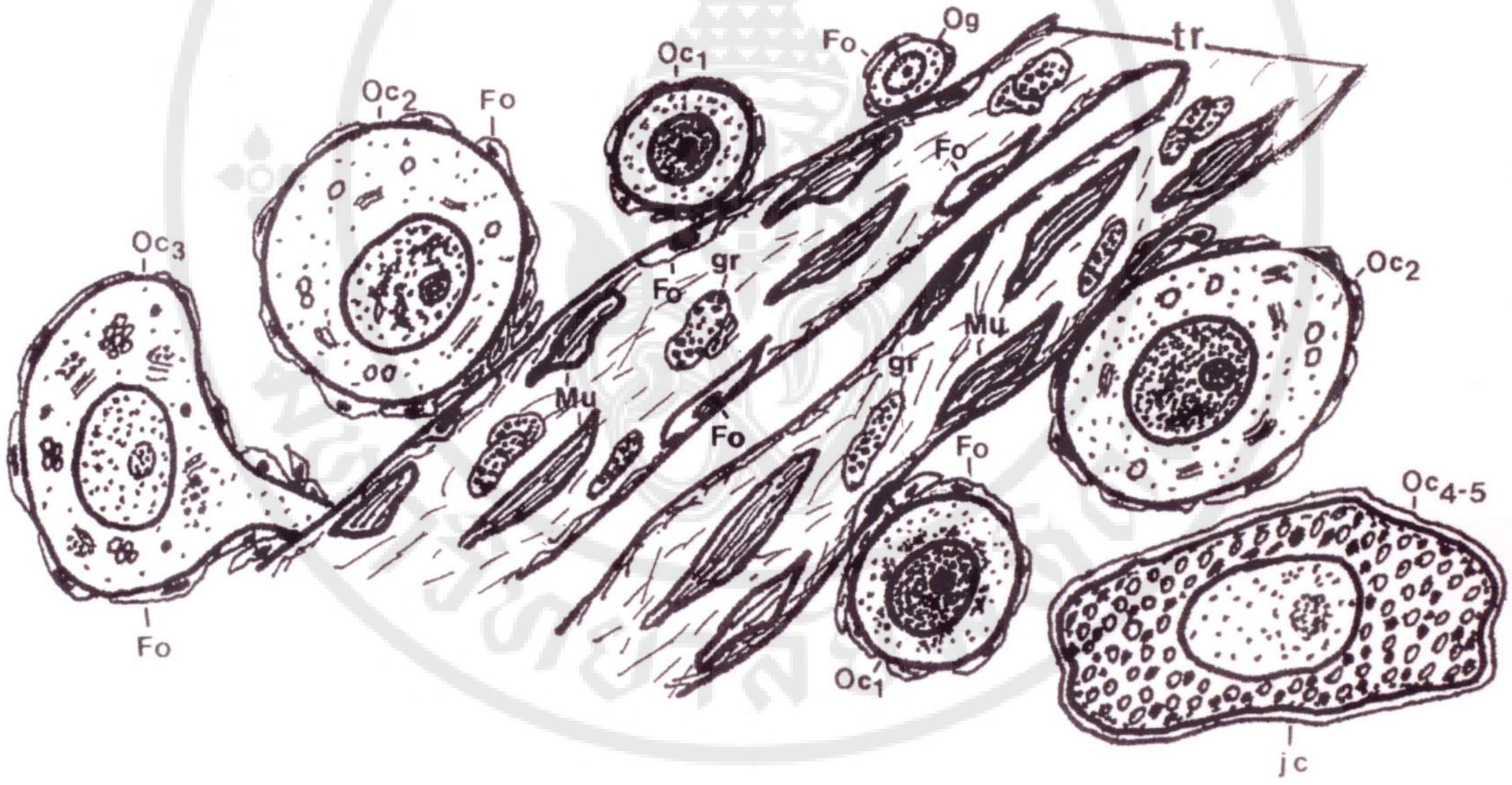
Oc3
Oc2
Fo
Oc1
Fo
Og
tr
Fo
Fo
gr
Mu
Fo
gr
Mu
Oc2
Fo
Fo
Oc4-5
Oc1
jc

Figure 8. Paraffin sections of the conical organ of 2-month-old *H. asinina*, stained with H&E.

A–B. Cross sections of the hepatopancreas (HP) showing the outer capsule (Ocp) separated from the inner capsule

C-D. Higher magnifications showing squamous epithelium covering the outer layer of gonadal capsule or outer capsule. The inner layer consists of collagen fibers, fibroblasts (F) and muscle cells (mu).

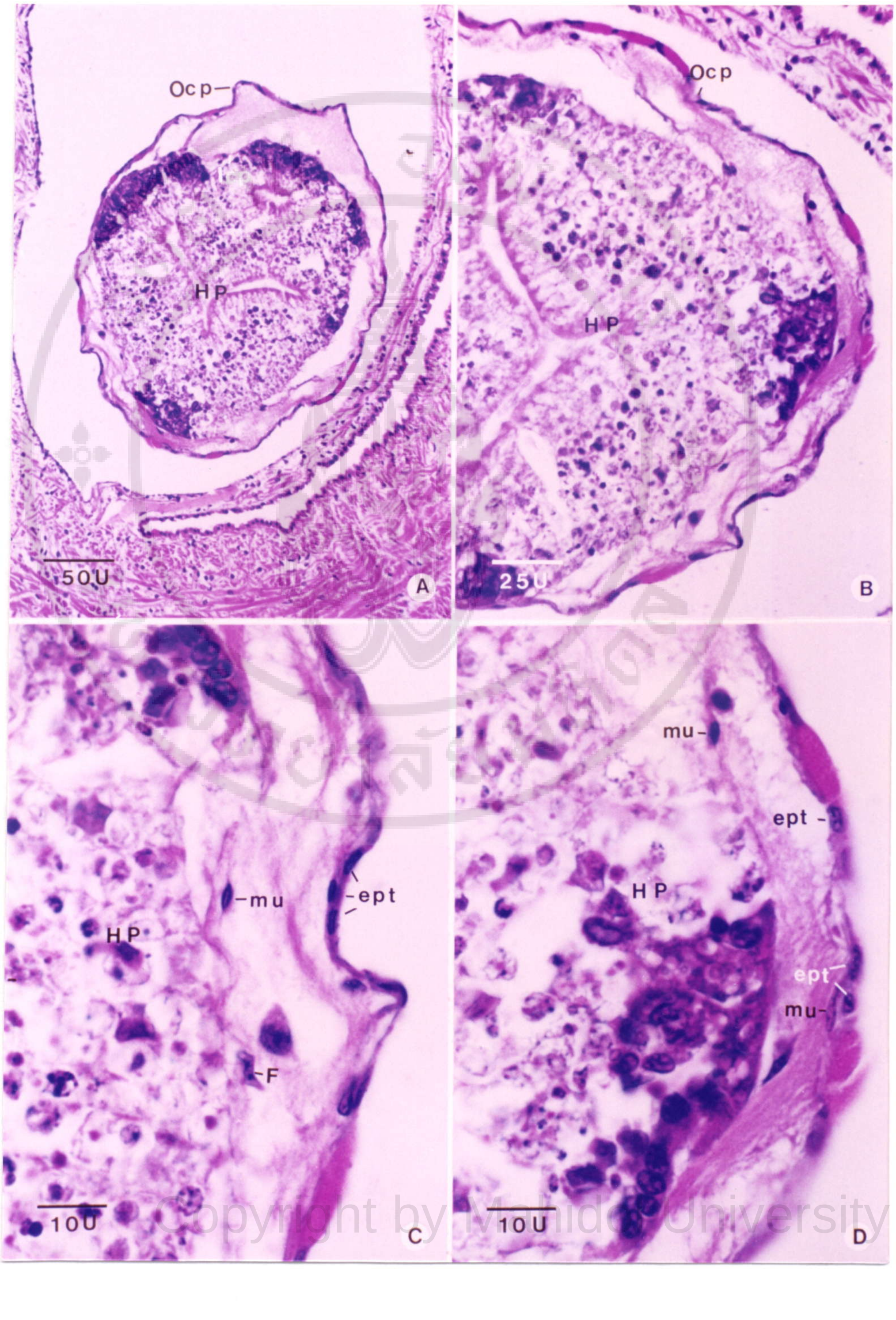
Ocp
HP
50U
A
Ocp
HP
25U
B
HP
mu
ept
F
10U
C
mu
ept
HP
ept
mu
10U
D

Figure 9. Paraffin sections of the hepatopancreas and the testis of 4-month-old *H.asinina*, stained with H&E.

A. Cross section of the testis which covers about a quarter of the hepatopancreas (HP).

B-C. Higher magnifications showing the hepatopancreas (HP) surrounded by the inner capsule (Icp) and the testicular tissue which is, in turn, surrounded by the outer capsule (Ocp). There are spermatogenic units in the testis.

D. High-power micrograph of the spermatogenic unit showing a central trabecula, spermatocytes (Sc), spermatids (St) and immature spermatozoa (Sz_1).

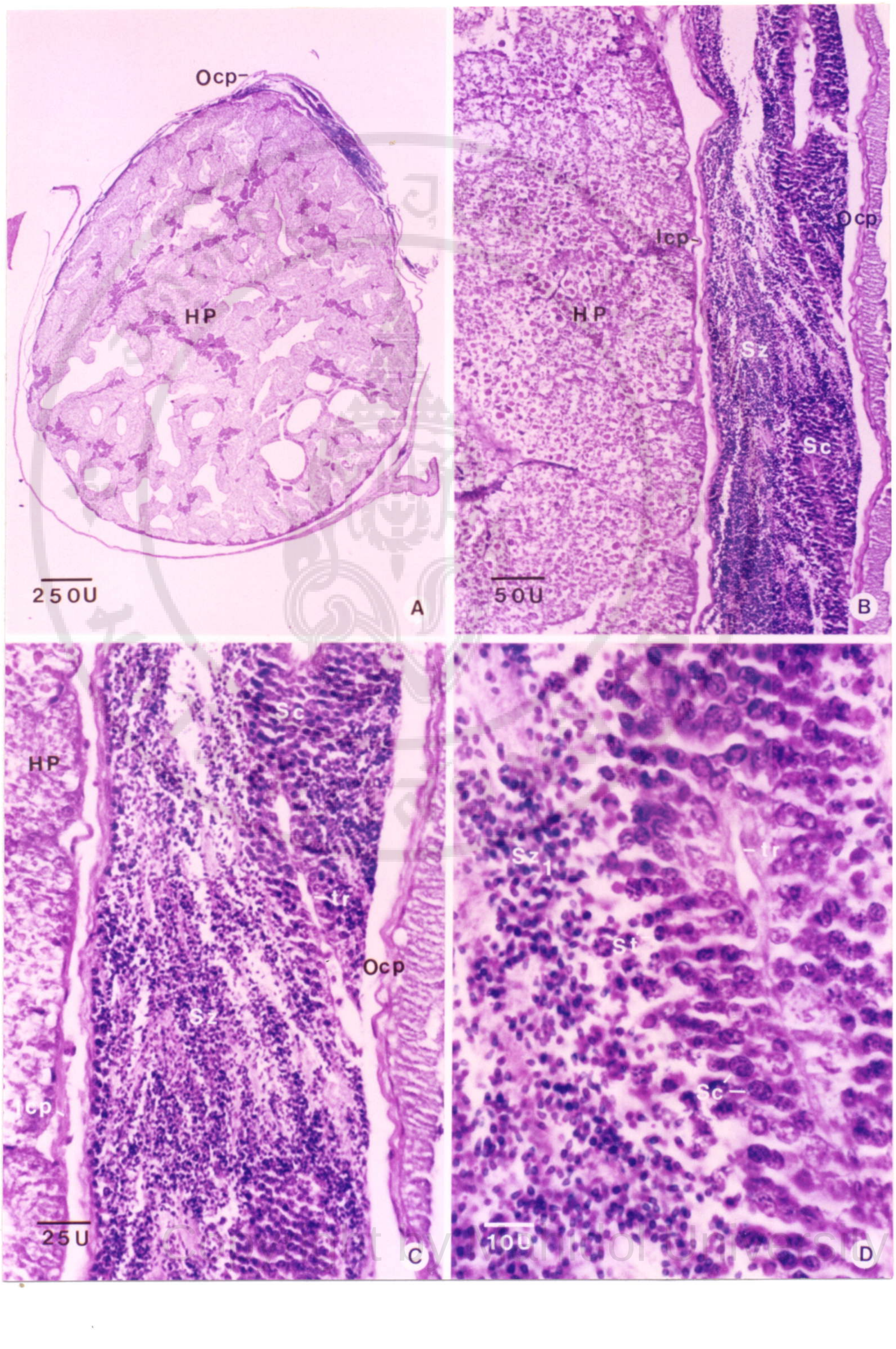
Ocp
HP
250U
A
Icp
HP
Ocp
Sz
Sc
50U
B
HP
Sc
tr
Ocp
Sz
Icp
25U
C
Sz
tr
St
Sc
10U
D

Figure 10. Paraffin sections of the hepatopancreas and the testis of 6-month-old *H.asinina*, stained with H&E.

A. Cross section of the testis which covers almost half of the hepatopancreas (HP).

B-C. Higher magnifications showing spermatogenic units. There are increasing numbers of spermatocytes (Sc), spermatids (st) and immature spermatozoa (Sz_1).

D. High-power micrograph of a spermatogenic unit showing trabecula (tr), spermatocytes, spermatids and immature spermatozoa whose nucleus is not condensed .

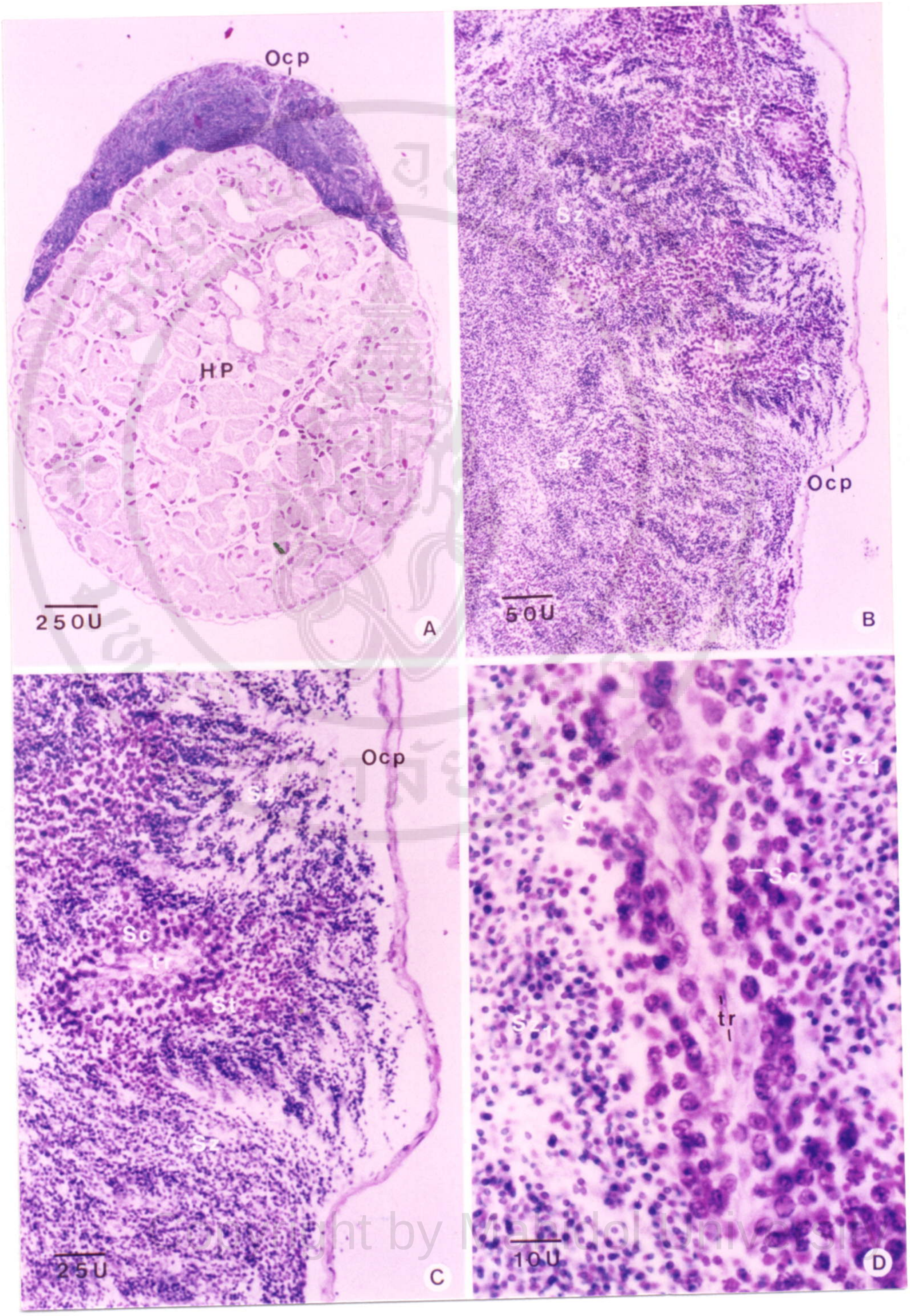
Ocp
HP
250U
A
Sc
Sz
Sz
St
Sz
Ocp
50U
B
Ocp
St
Sc
tr
St
Sz
25U
C
Sz1
St
Sc
tr
Sz1
10U
D

Figure 11. Paraffin sections of the hepatopancreas (HP) and the ovary of 6-month-old *H. asinina*, stained with H&E.

A. Cross section of a very small ovary covered by outer capsule (Ocp).

B-D. Higher magnifications showing stage 1 oocyte (Oc_1) and stage 2 oocyte (Oc_2) attached to the inner capsule (Icp) (tr-trabeculae).

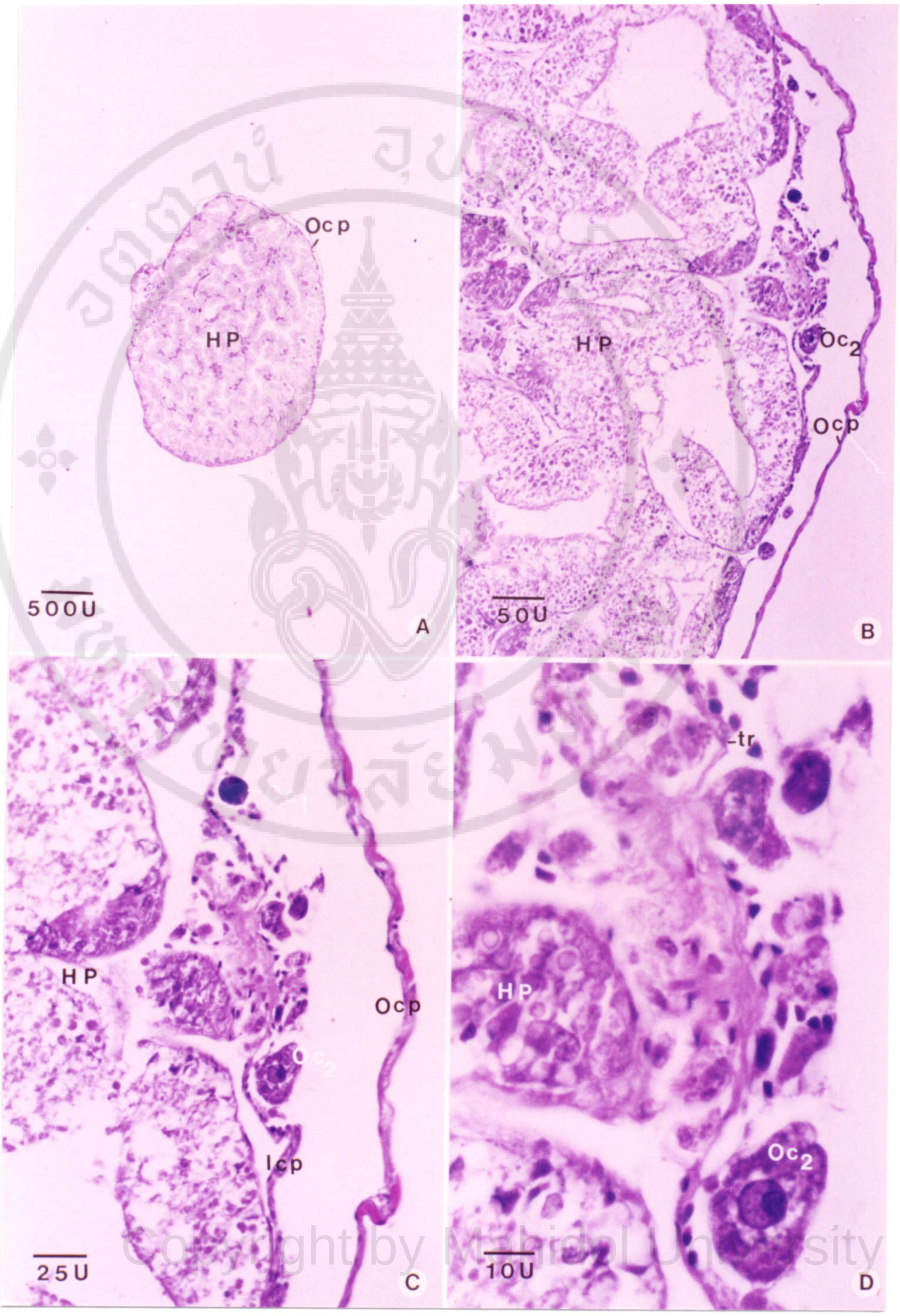
Ocp
HP
500U
A
HP
Oc2
Ocp
50U
B
HP
Ocp
Oc2
Icp
25U
C
-tr
HP
Oc2
10U
D

Figure 12. Paraffin sections of the hepatopancreas and the testis of 7-month-old *H. asinina*, stained with H&E.

A. Cross sections of the testis which surrounds about half of the hepatopancreas (HP).

B-D. Higher magnifications showing spermatogenic units containing spermatocytes (Sc), spermatids (St) and spermatozoa (Sz).

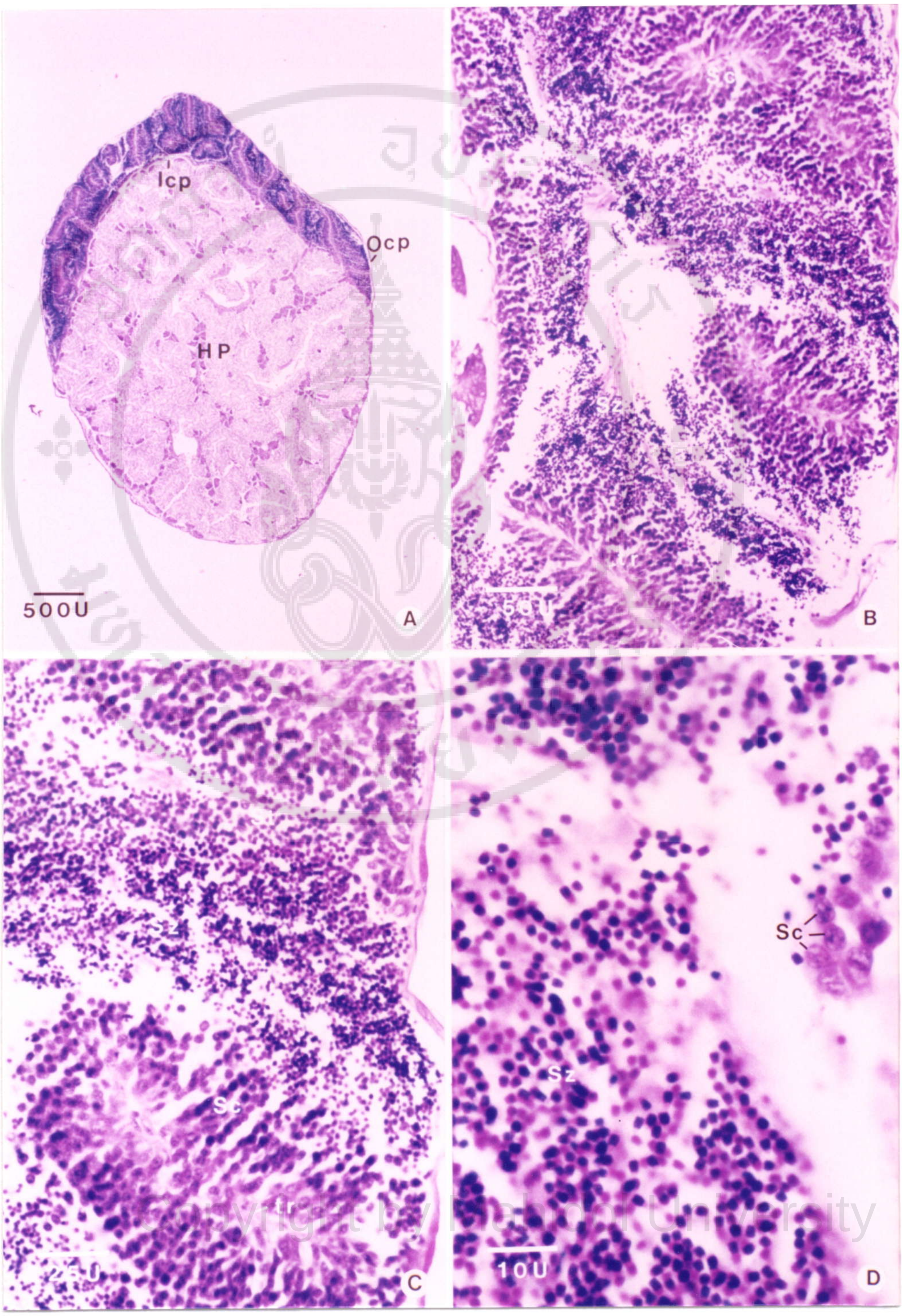
Icp
Ocp
HP
500U
A
Sc
Sz
50U
B
Sz
Sc
tr
25U
C
Sc
Sz
10U
D

Figure 13. Paraffin sections of the hepatopancreas (HP) and the ovary of 7-month-old *H. asinina*, stained with H&E.

A. Cross section of the small ovary surrounded by the outer capsule (Ocp).

B-D. Higher magnifications showing that early stage oocytes (Oc_1, Oc_2) are attached to the inner capsule (Icp). The trabeculae (tr) extend from the outer capsule into the ovary. Stages 1 and 2 oocytes are increased in number.

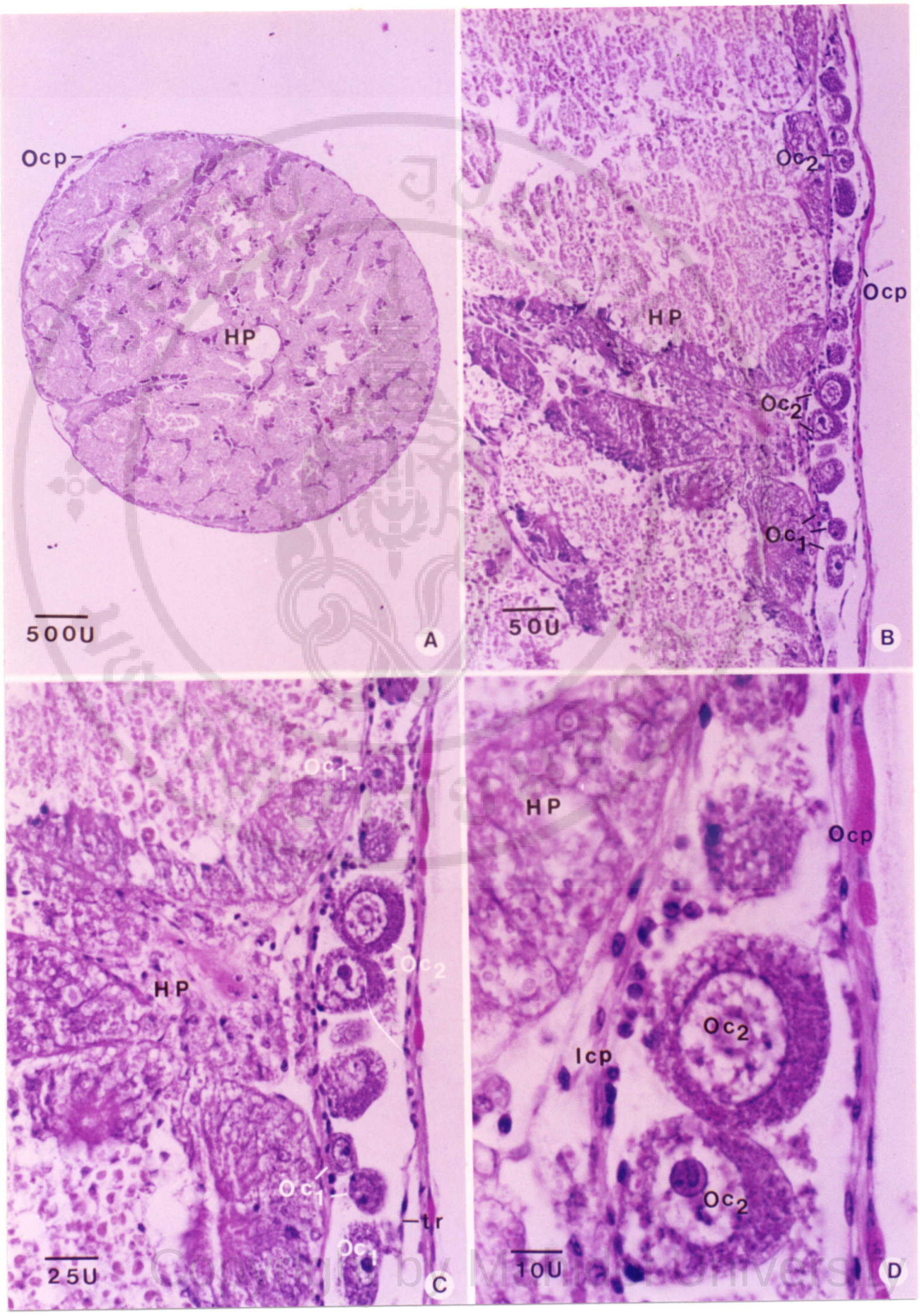
Ocp
HP
500U
A
Oc2
Ocp
HP
Oc2
Oc1
50U
B
Oc1
HP
Oc2
Oc1
tr
Oc1
25U
C
HP
Ocp
Icp
Oc2
Oc2
10U
D

Figure 14. Paraffin sections of the testis of 11-month-old *H. asinina*, stained with H&E.

A. Cross section of the testis which covers almost all of the periphery of the hepatopancreas (HP) (Ocp-outer capsule, Icp-inner capsule).

B&C. Higher magnifications showing that spermatogenic units are completely developed.

D. High-power micrograph showing a spermatogenic unit consisting of trabecula (tr), spermatocytes (Sc), spermatids (St) and spermatozoa (Sz).

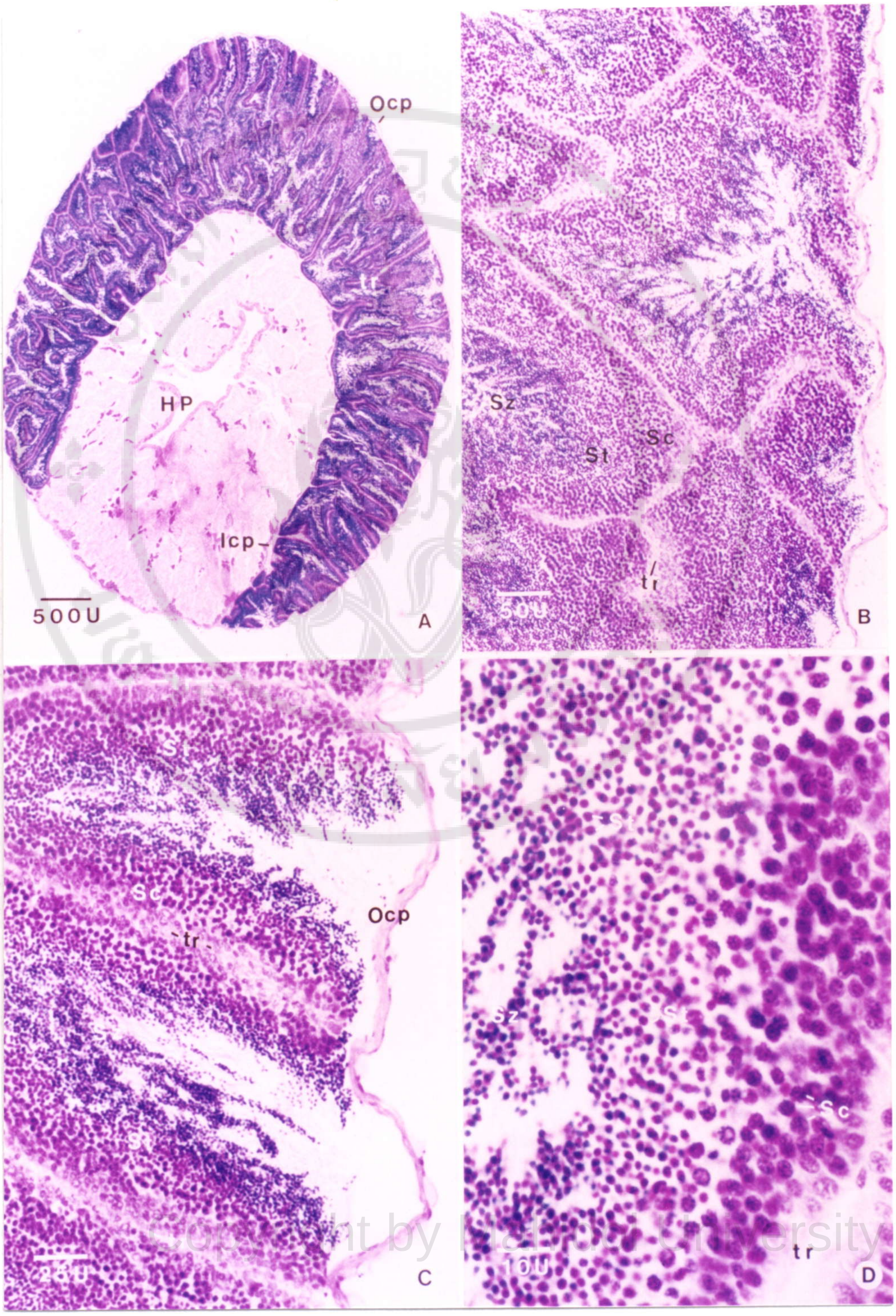
Ocp
HP
Icp
500U
A
Sz
St
Sc
tr
50U
B
S
Sc
tr
Ocp
S
25U
C
Sz
Sc
Sc
tr
10U
D

Figure 15. Paraffin sections of the ovary of 11-month-old *H. asinina*, stained with H&E.

A. Cross-section of the ovary which surrounds the entire periphery of the hepatopancreas (HP).

B-D. Higher magnifications showing that each oogenetic unit consists of an axis of trabecula (tr) surrounded by early stage oocytes (Oc_1, Oc_2, Oc_3) and late stage oocytes (Oc_4, Oc_5). The connective tissue trabeculae extend from the outer capsule (Ocp) into the ovary and separate the ovary into small compartments.

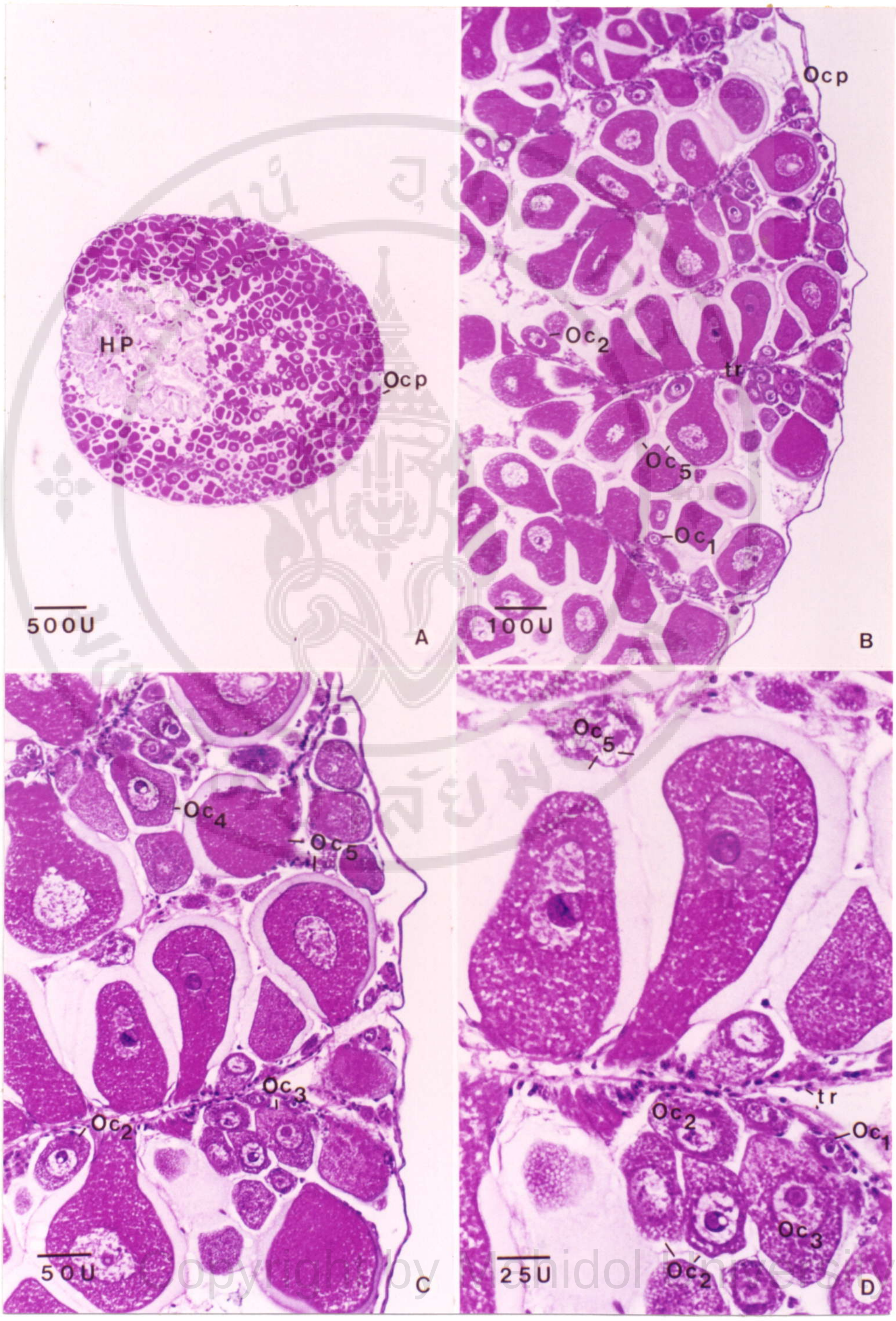
HP
Ocp
500U
A
Ocp
Oc_2
tr
Oc_5
Oc_1
100U
B
Oc_4
Oc5
Oc_3
Oc_2
50U
C
Oc_5
tr
Oc_2
Oc_1
Oc_3
Oc_2
25U
D

Figure 16. Immunofluorescence micrographs of the ovary of *H. asinina*.

A. Cross section of the ovary in proliferative phase showing no staining with anti-aELH.

B-D. Sections of the ovary in proliferative phase stained with anti-aELH, showing positive staining in the trabeculae (tr), both capsules (Ocp, Icp) and cytoplasm of stages 1 oocytes (Oc_1).

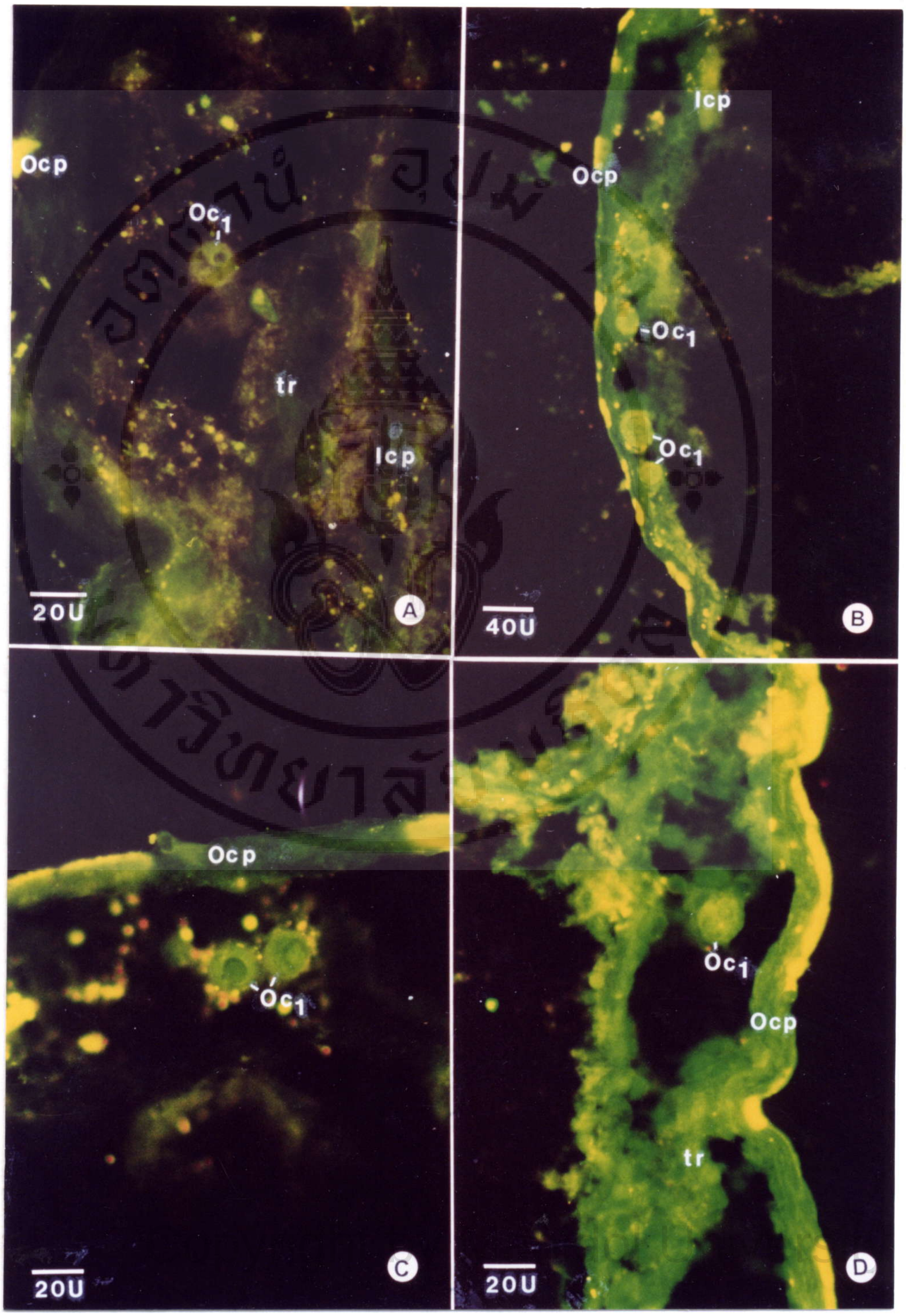
Ocp
Oc1
tr
Icp
20U
A
Icp
Ocp
Oc1
Oc1
40U
B
Ocp
Oc1
20U
C
Oc1
Ocp
tr
20U
D

Figure 17. Light micrographs of the ovary in proliferative phase, stained with anti-aELH by using immunogold method with silver enhancement.

A&B. Control sections of the ovary showing no staining.

C&D. Sections stained with anti-aELH, showing strong staining in granulated cells (gr) within the inner capsule (Icp) and moderate staining in the cytoplasm of immature oocytes (Oc_1, Oc_2, Oc_3). Both trabeculae and capsules (Ocp, Icp) are weakly stained.

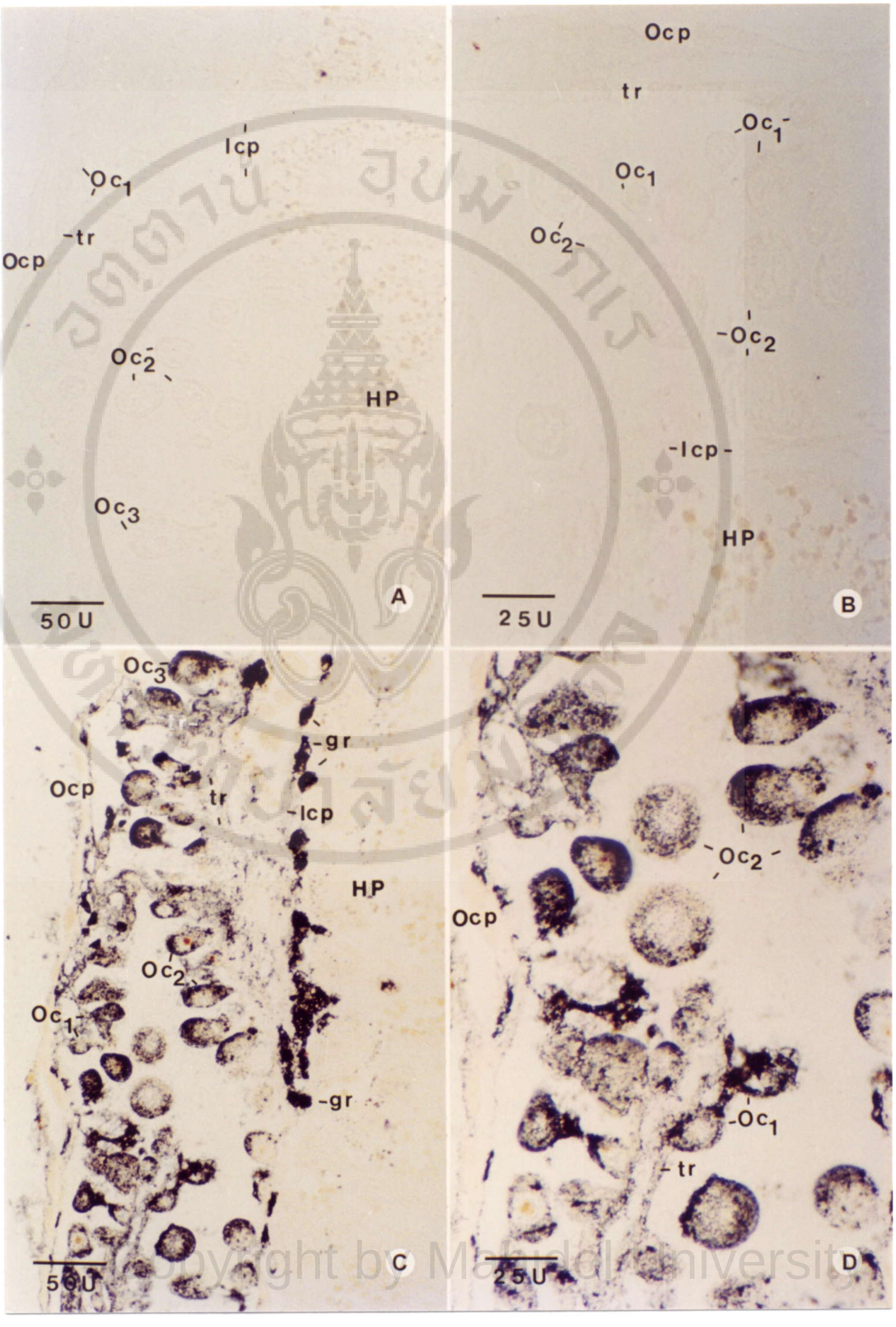
lcp
Oc1
tr
Ocp
Oc2
HP
Oc3
50U
A
Ocp
tr
Oc1
Oc1
Oc2
Oc2
lcp
HP
25U
B
Oc3
gr
Ocp
tr
lcp
HP
Oc2
Oc1
gr
50U
C
Ocp
Oc2
Oc1
tr
25U
D

Figure 18. Light micrographs of the ovary in proliferative phase, stained with anti-aELH by using immunoperoxidase method.

A. Control sections of the ovary showing no staining.

B-D. Sections stained with anti-aELH, showing intense staining in granulated cells (gr) within the inner capsule (Icp). Moderate staining is seen in the connective tissue proper of trabeculae (tr), both capsules (Ocp, Icp), and cytoplasm of the immature oocytes (Oc_1, Oc_2, Oc_3) (HP-hepatopancreas).

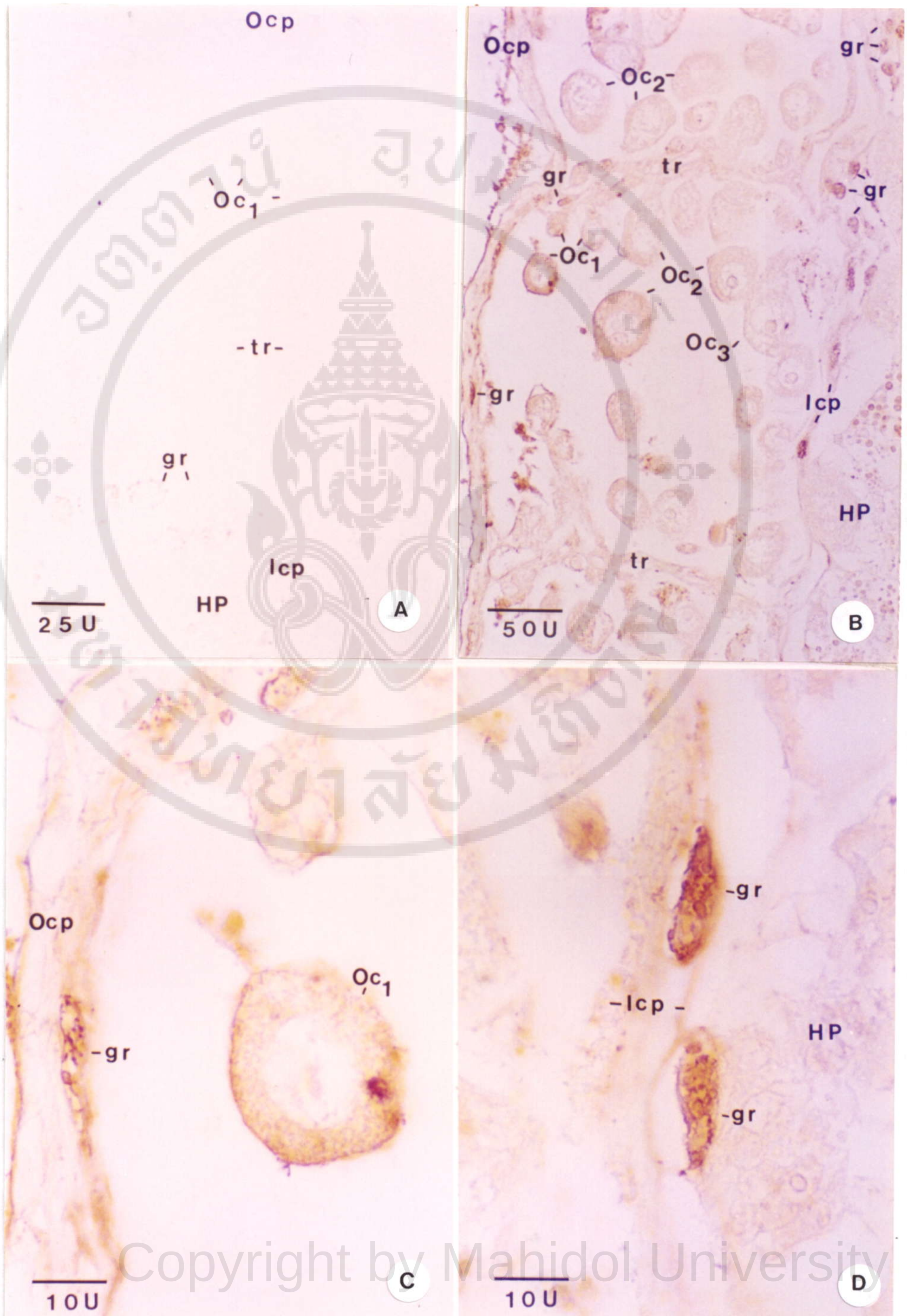
Ocp
Oc1
tr
gr
Icp
HP
25 U
A
Ocp
Oc2
gr
tr
gr
Oc1
Oc2
Oc3
gr
Icp
HP
tr
50 U
B
Ocp
gr
Oc1
10 U
C
gr
Icp
HP
gr
10 U
D

Figure 19. Immunofluorescence micrographs of the mature ovary of *H. asinina*.

A. Control section of the ovary in mature phase showing no staining and non-specific fluorescence in the jelly coat (jc) of mature oocytes (Oc_5).

B-D. Sections of the ovary in mature phase stained with anti-aELH showing positive staining in the outer capsule (Ocp) and trabeculae (tr).

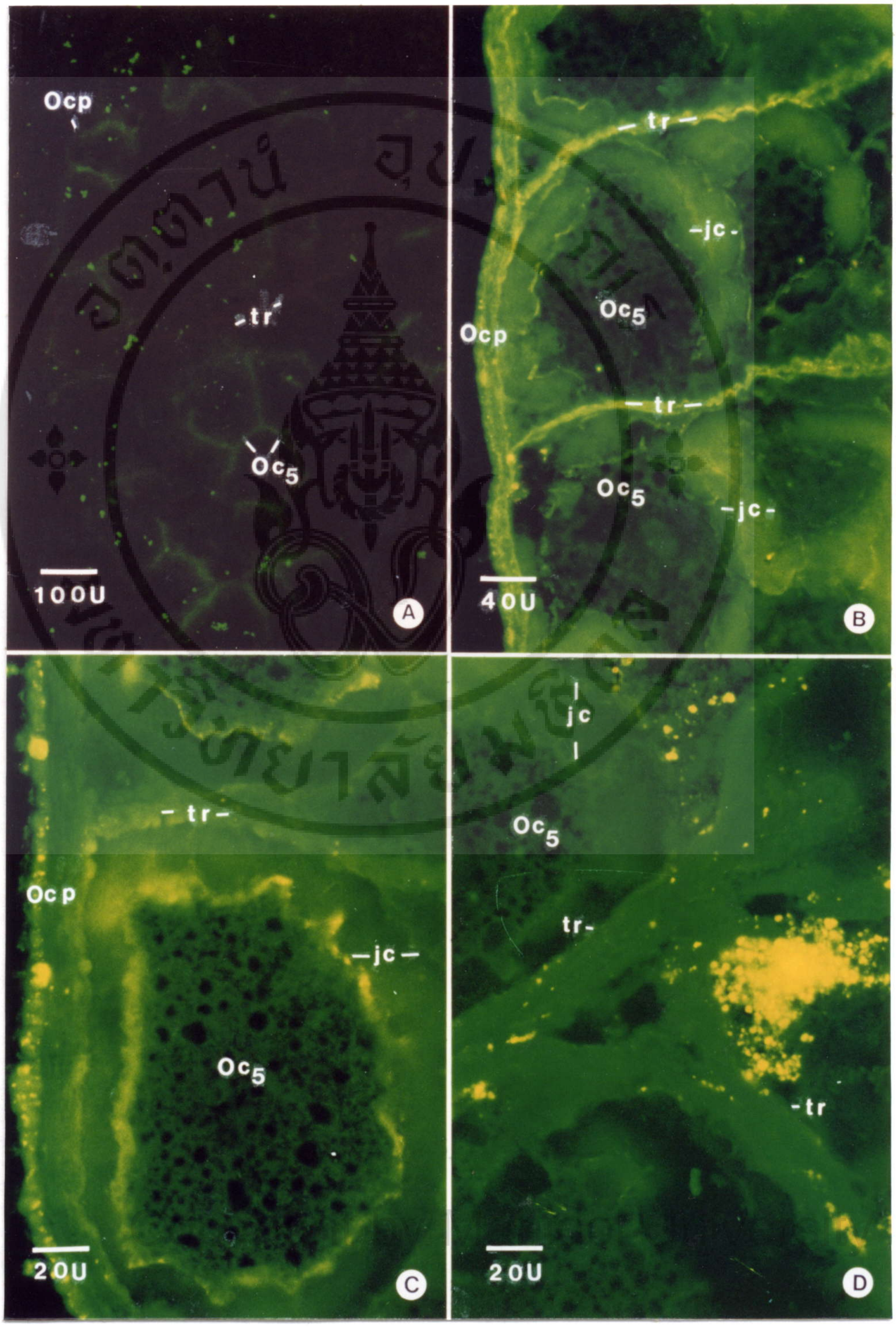
Ocp
tr
Oc5
100U
A
tr
jc
Ocp
Oc5
tr
Oc5
jc
40U
B
tr
Ocp
jc
Oc5
20U
C
jc
Oc5
tr
tr
20U
D

Figure 20. Photomicrographs of the ovary in mature phase, stained with anti-aELH by using immunogold method with silver enhancement.

A. Control section of the mature ovary counter-stained with Mayer's hematoxylin showing no staining in the outer capsule (Ocp), trabeculae (tr), and cytoplasm of stage 5 oocytes (Oc_5). The non-specific binding appears in the jelly coat (jc) of stage 5 oocytes.

B-D. Sections of the mature ovary showing positive staining in the trabeculae (tr) while the non-specific binding appears in the jelly coat (jc) of stage 5 oocytes (Oc_5).

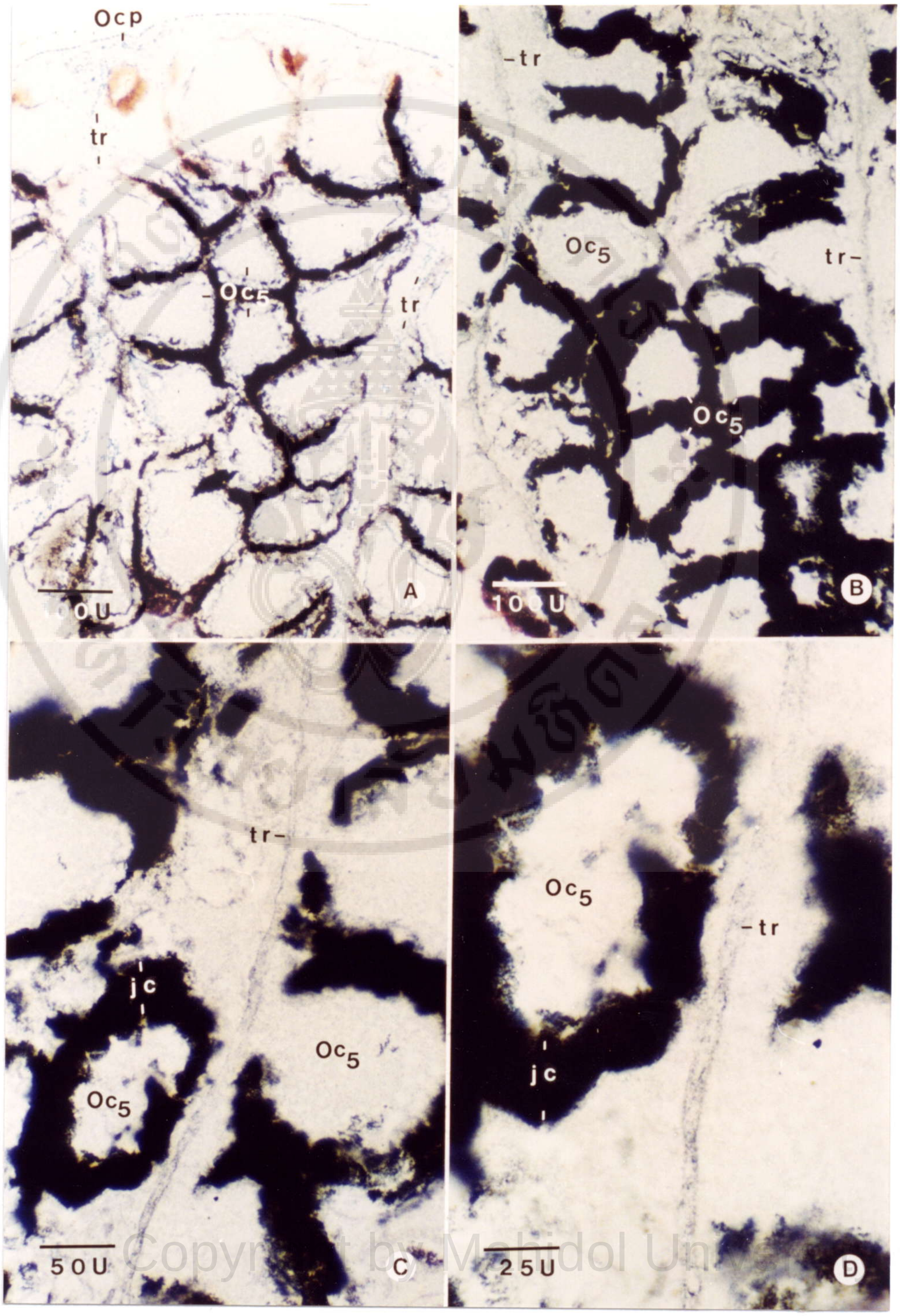
Ocp
tr
Oc$_5$
tr
100U
A
tr
Oc$_5$
tr
Oc$_5$
100U
B
tr
jc
Oc$_5$
Oc$_5$
50U
C
Oc$_5$
tr
jc
25U
D

Figure 21. Photomicrographs of the ovary in mature phase, stained with anti-aELH by using immunogold method with silver enhancement and counterstained with Mayer's hematoxylin.

A. Control section of the mature ovary showing no staining in the trabeculae. The non-specific binding appears in the jelly coat of mature oocytes (Oc_5).

B-D. Sections of the mature ovary showing positive staining in the trabeculae (tr) and muscle cells (mu). The non-specific binding is seen in the jelly coat (jc) of mature oocytes (Oc_5).

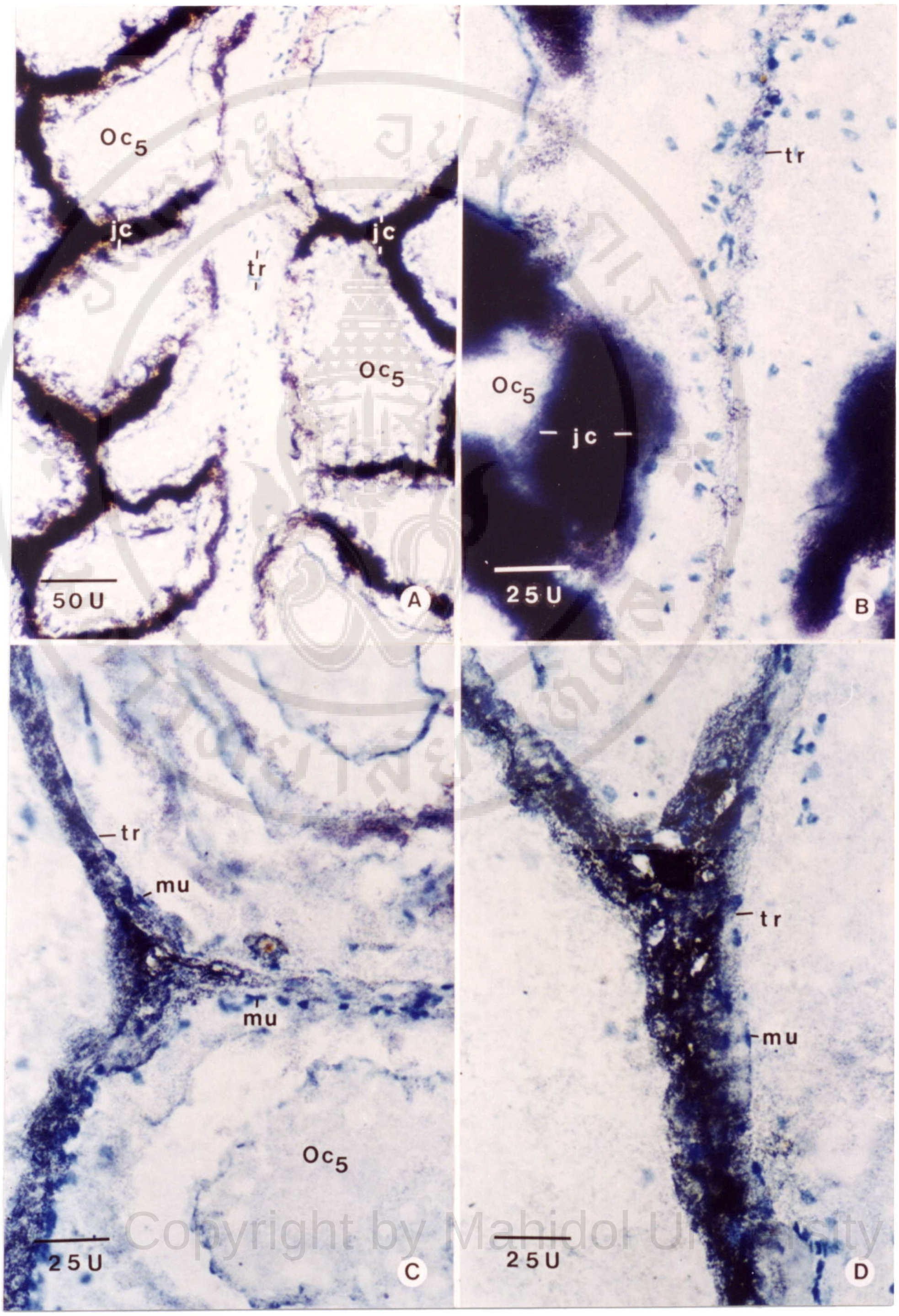
Oc5
jc
tr
jc
Oc5
50 U
A
tr
Oc5
jc
25 U
B
tr
mu
mu
Oc5
25 U
C
tr
mu
25 U
D

Figure 22. **A-D.** Control sections of the mature ovary, stained with 0.05 M TBS by using immunoperoxidase method. Low-power micrographs in A&B and medium-power micrographs in C&D show no staining in the outer capsule (Ocp), trabeculae (tr) and mature oocytes (Oc_5).


Ocp
tr
Oc5
tr
100U
A
tr
Oc5
tr
100U
B
Ocp
tr
Oc5
tr
50U
C
tr
Oc5
50U
D

Figure 23. **A-D.** Sections of the mature ovary, stained with anti-aELH by using immunoperoxidase method. In A-C, the outer capsule (Ocp), inner capsule (Icp) and trabeculae (tr) show moderate staining while the cytoplasm of mature oocytes (Oc_5) are weakly stained. High-power micrograph in D shows that the granulated cell (gr) is intensely stained (jc-jelly coat, HP-hepatopancreas).

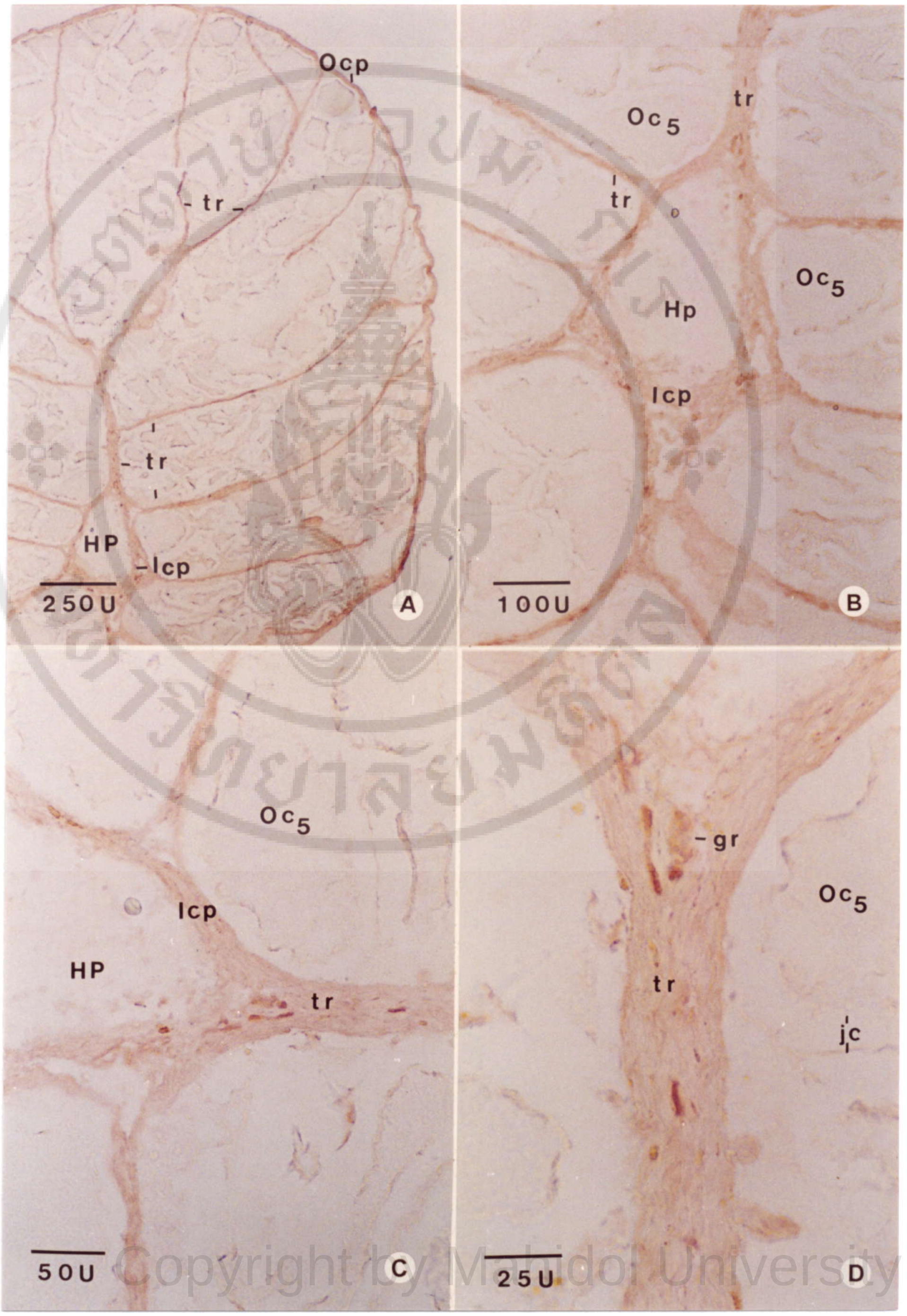
Ocp
tr
tr
HP
lcp
250U
A
Oc$_5$
tr
tr
Oc$_5$
Hp
lcp
100U
B
Oc$_5$
lcp
HP
tr
50U
C
gr
Oc$_5$
tr
jc
25U
D

Figure 24. **A-D.** Sections of the mature ovary, stained with anti-aELH by using immunoperoxidase method. In A-C, moderate staining is seen in the trabeculae (tr) and outer capsule (Ocp). The cytoplasm of stage 5 oocytes (Oc_5) are weakly stained (jc-jelly coat). In D, the granulated cells (gr) in the trabeculae show strong positive staining.

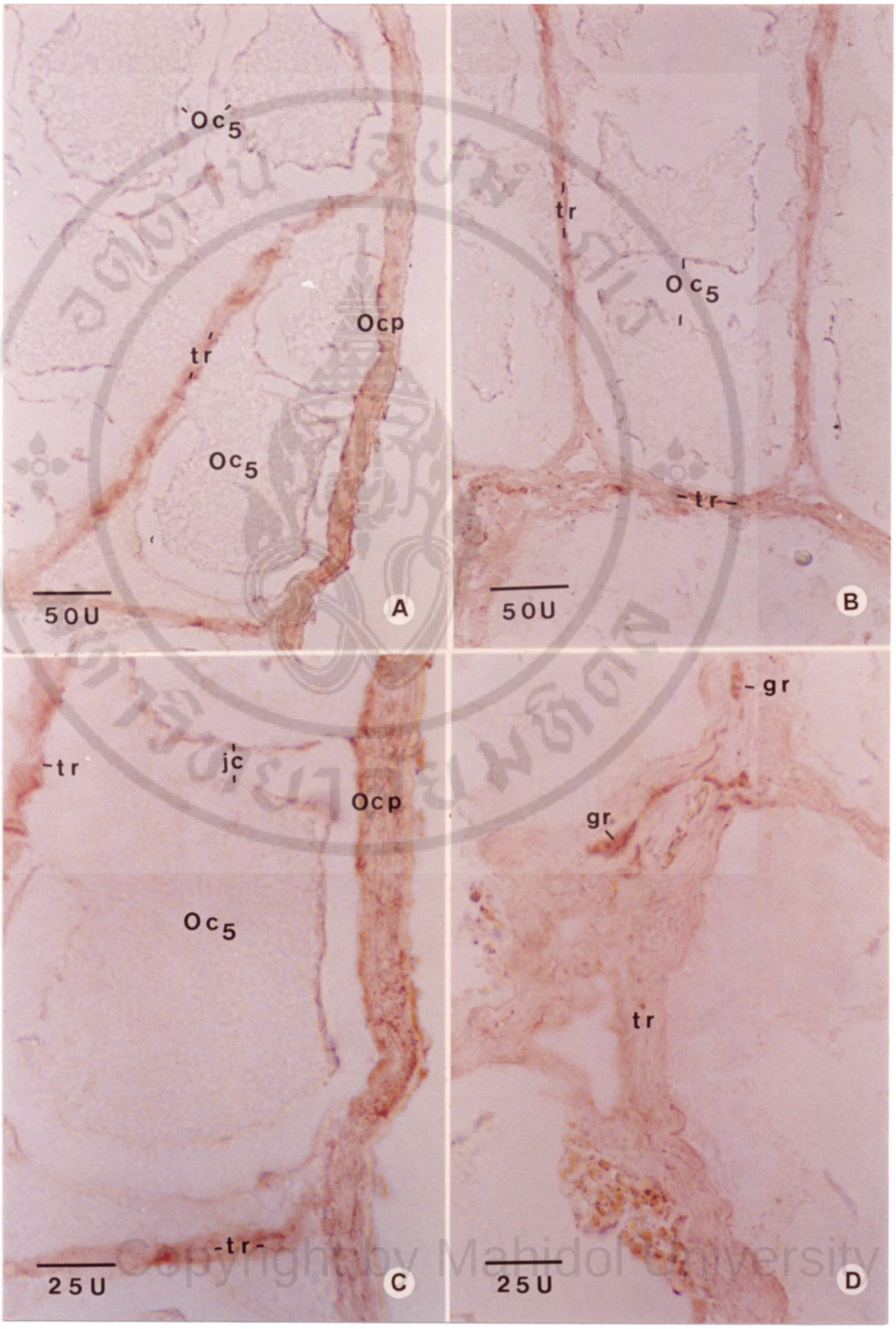
Oc5
Ocp
tr
Oc5
50U
A
tr
Oc5
tr
50U
B
tr
jc
Ocp
Oc5
tr
25U
C
gr
gr
tr
25U
D

Figure 25. A-D. Control sections of the mature ovary, stained with 0.05 M TBS by using immunoperoxidase method and counter-stained with Mayer's hematoxylin. Low-power micrographs in A&B and high-power micrographs in C&D show no staining in the outer capsule (Ocp), trabeculae (tr), muscle cells (mu) and mature oocytes (Oc_5) with thick jelly coat (jc).

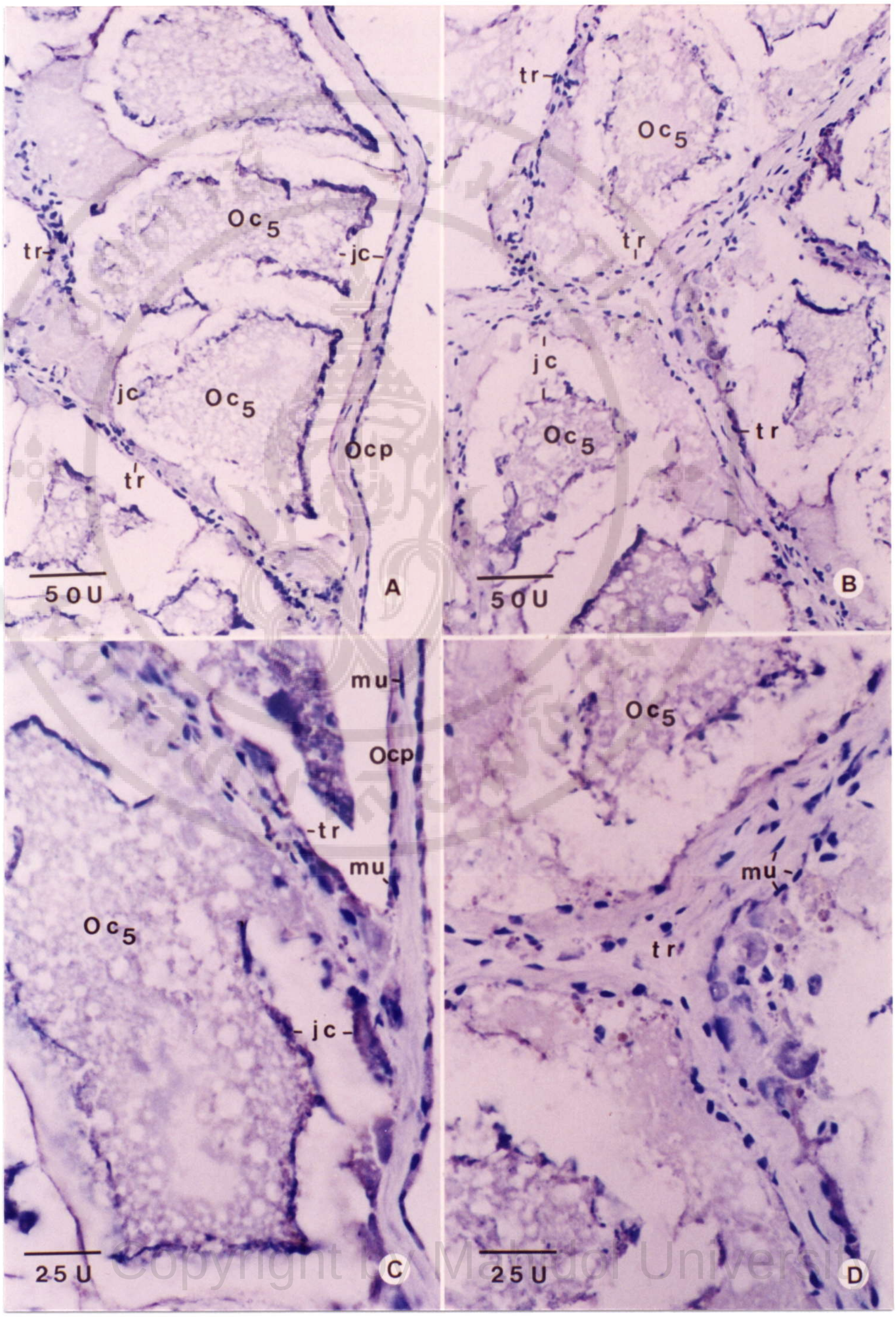
tr
Oc_5
jc
jc
Oc_5
tr
Ocp
50U
A
tr
Oc_5
tr
jc
Oc_5
tr
50U
B
mu
Ocp
tr
mu
Oc_5
jc
25U
C
Oc_5
mu
tr
25U
D

Figure 26. **A-D.** Sections of the mature ovary, stained with anti-aELH by using immunoperoxidase method and counter-stained with Mayer's hematoxylin. The granulated cells (gr) and muscle cells (mu) show strong positive staining. While the trabeculae (tr) and outer capsule (Ocp) are moderately stained and the cytoplasm of mature oocytes (Oc_5) is weakly stained (jc-jelly coat).

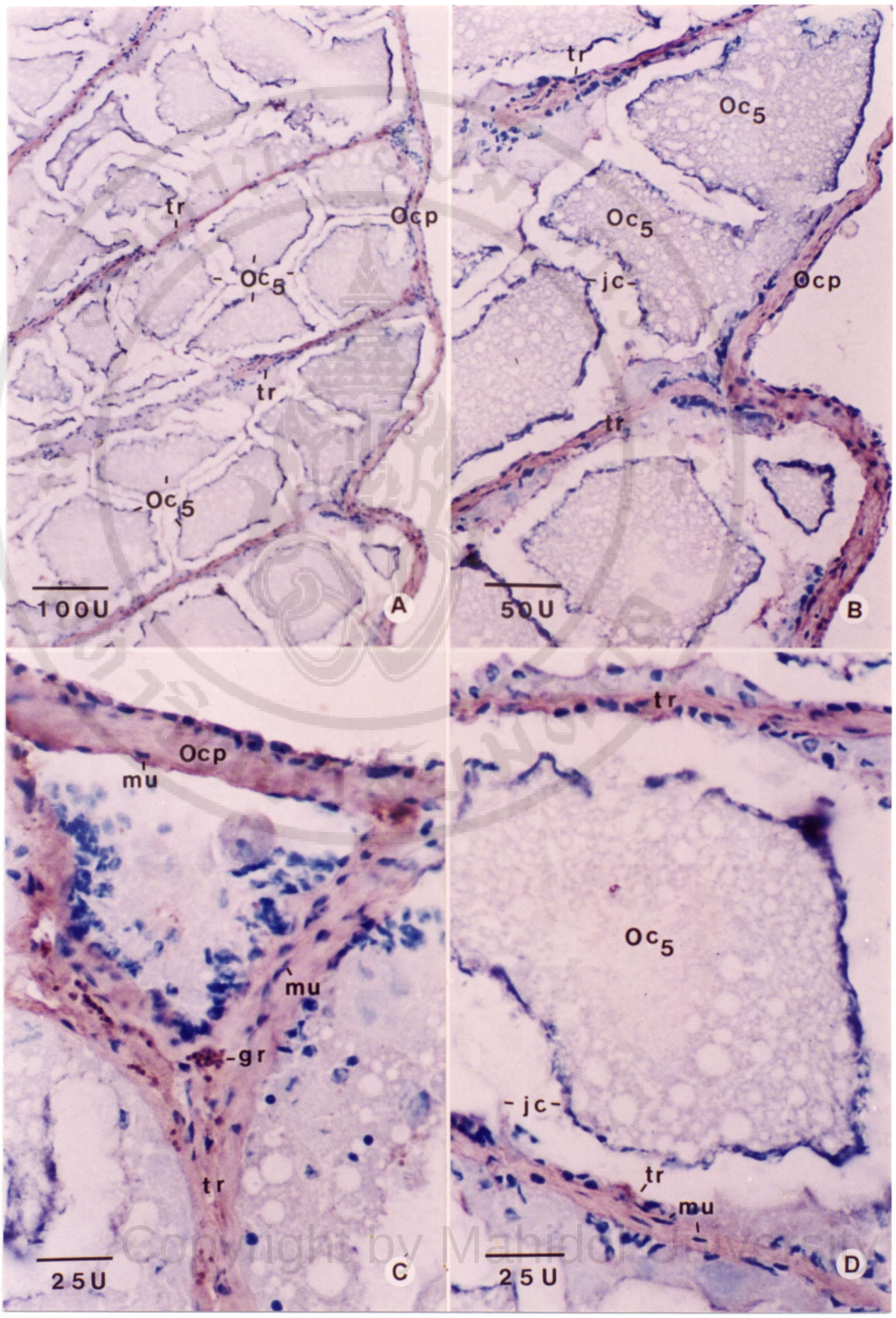
tr
Ocp
Oc5
tr
Oc5
100U
A
tr
Oc5
Oc5
jc
Ocp
tr
50U
B
Ocp
mu
mu
gr
tr
25U
C
tr
Oc5
jc
tr
mu
25U
D

Figure 27. A-D. Light micrographs of the mature ovary, stained with anti-aELH by using immunoperoxidase method and counter-stained with Mayer's hematoxylin. In A, anti-aELH exhibits staining in the trabeculae (tr), while the cytoplasm of late stage oocytes (Oc_5) surrounded by thick jelly coat (jc) are only weakly stained. In B-D, the granulated cells (gr) and muscle cells (mu) in the trabeculae are intensely stained.

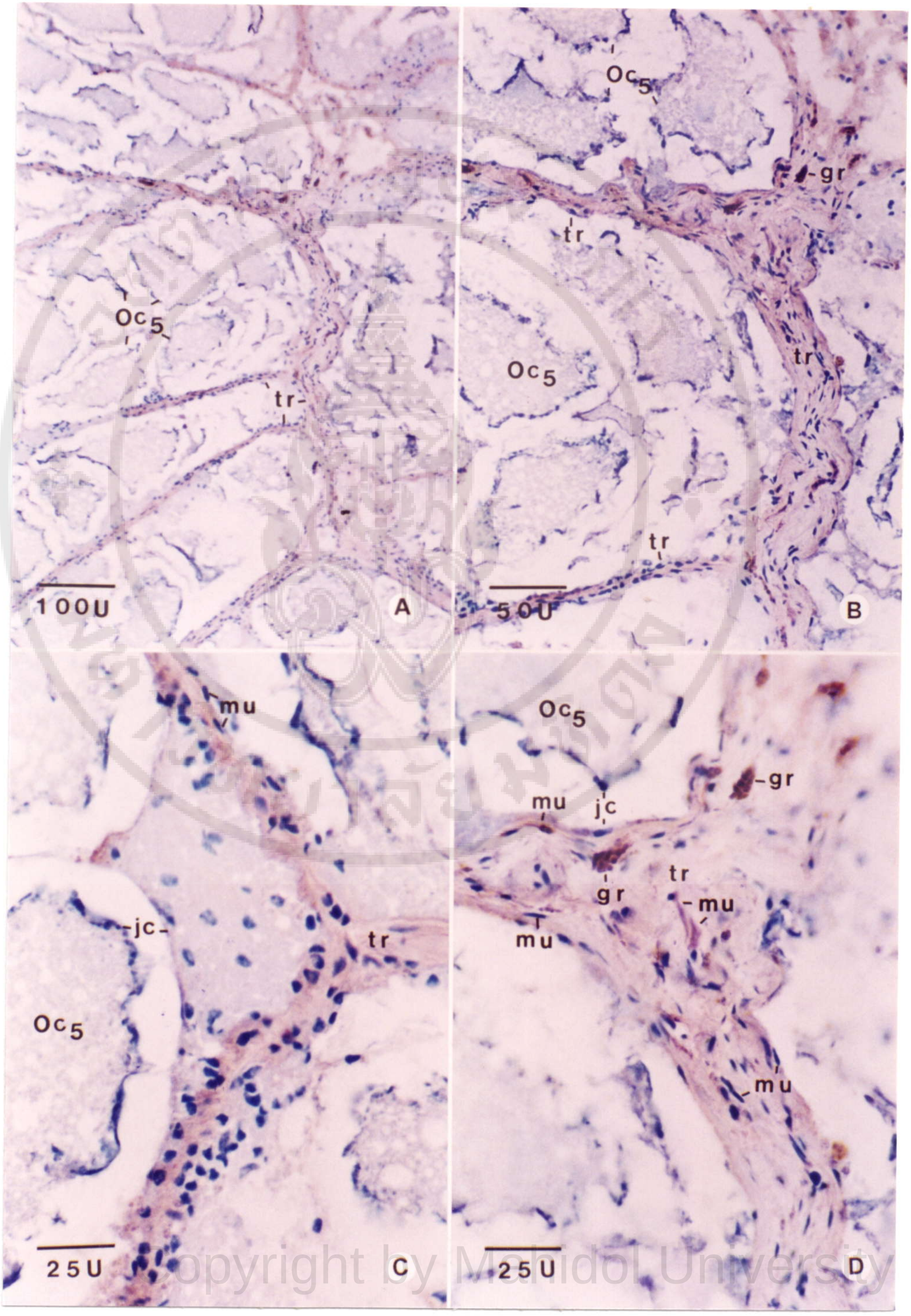
Oc5
tr
100U
A
Oc5
gr
tr
tr
Oc5
tr
50U
B
mu
jc
tr
Oc5
25U
C
Oc5
gr
mu
jc
gr
tr
mu
mu
mu
25U
D

Figure 28. Immunofluorescence micrographs of the mature testis of *H. asinina*.

A. Control section of the mature testis showing non-specific fluorescence in male germ cells and spermatozoa (Sz).

B-D. Sections stained with anti-aELH showing positive staining in the outer capsule (Ocp) and trabeculae (tr) of the testis.

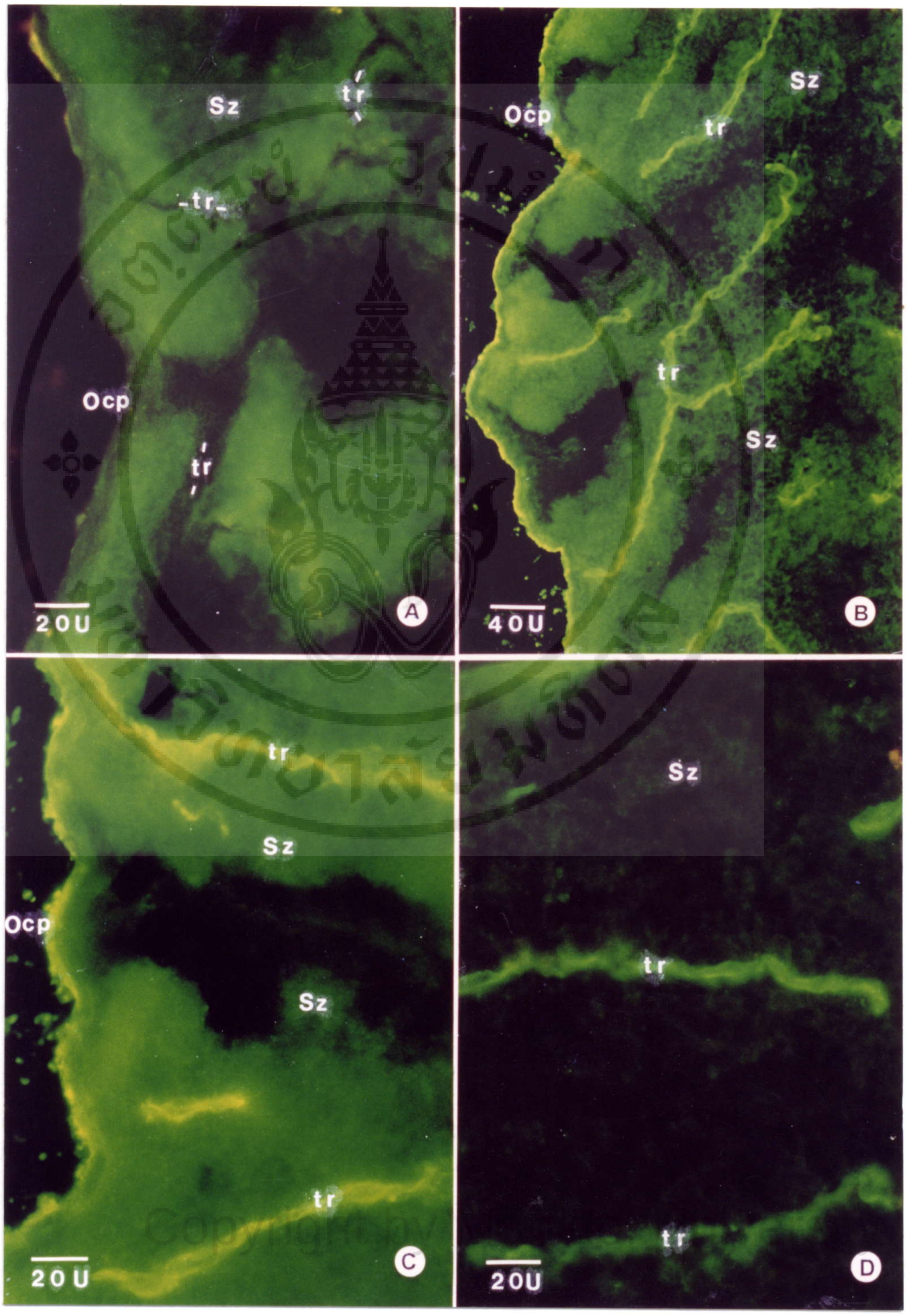
Sz
tr
tr
Ocp
tr
20U
A
Ocp
Sz
tr
tr
Sz
40U
B
tr
Sz
Ocp
Sz
tr
20U
C
Sz
tr
tr
20U
D

Figure 29. Light micrographs of the testis in mature phase, stained with anti-aELH by using immunogold method with silver enhancement.

A&B. Control sections showing no staining in the trabeculae (tr), outer capsule (Ocp), male germ cells and spermatozoa (Sz).

C&D. Sections stained with anti-aELH showing strong positive staining in the outer capsule and trabeculae, while male germ cells and spermatozoa are not stained.

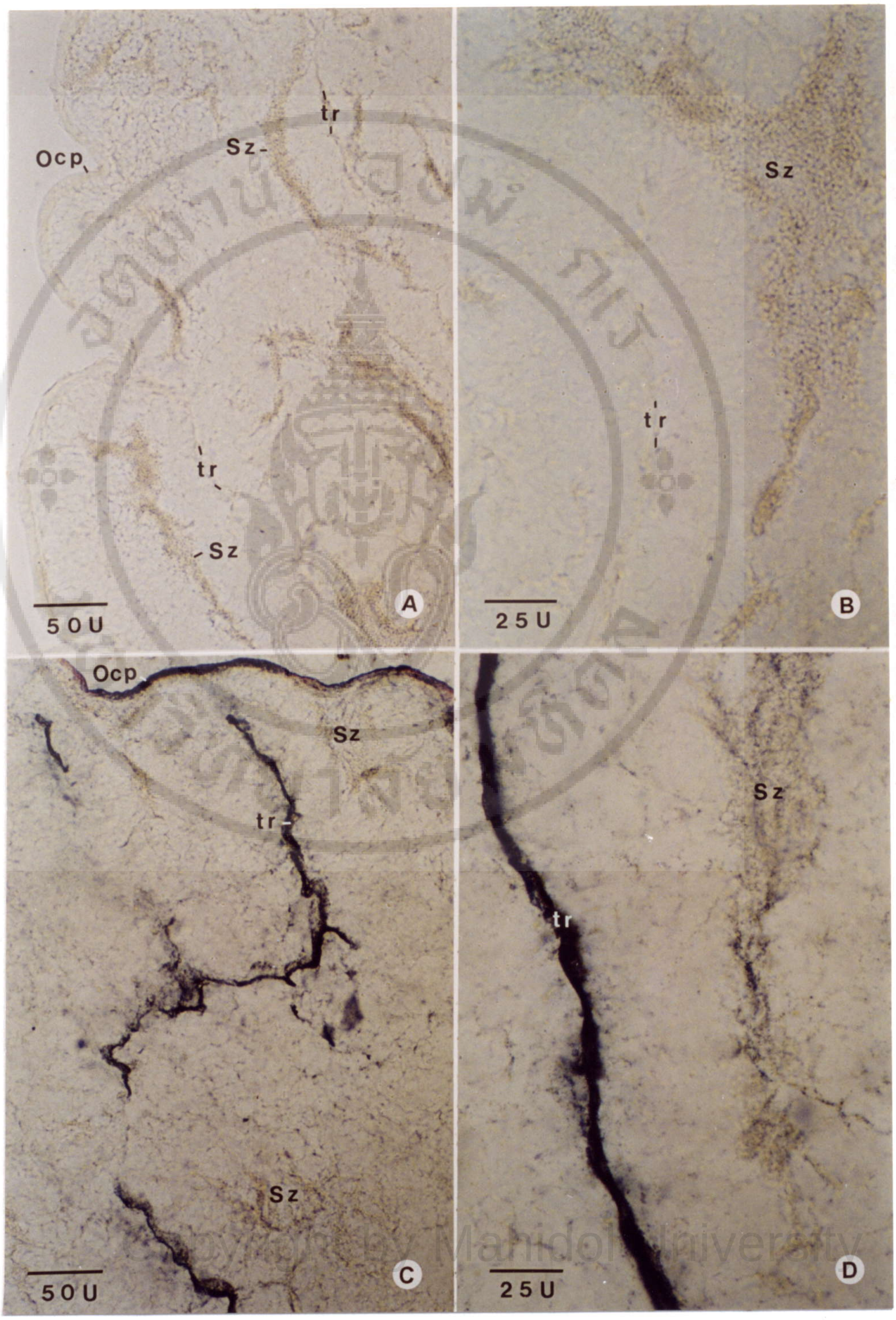
Ocp
Sz
tr
tr
Sz
50U
A
Sz
tr
25U
B
Ocp
Sz
tr
Sz
50U
C
Sz
tr
25U
D

Figure 30. Light micrographs of the testis in mature phase, stained with anti-aELH by using immunogold method with silver enhancement and counter-stained with Mayer's hematoxylin.

A&B. Control sections showing no staining in the trabeculae (tr), outer capsule (Ocp), male germ cells and spermatozoa (Sz).

C&D. Sections stained with anti-aELH showing strong positive staining in the trabeculae and moderate staining in the outer capsule (Ocp), while male germ cells and spermatozoa (Sz) are not stained.

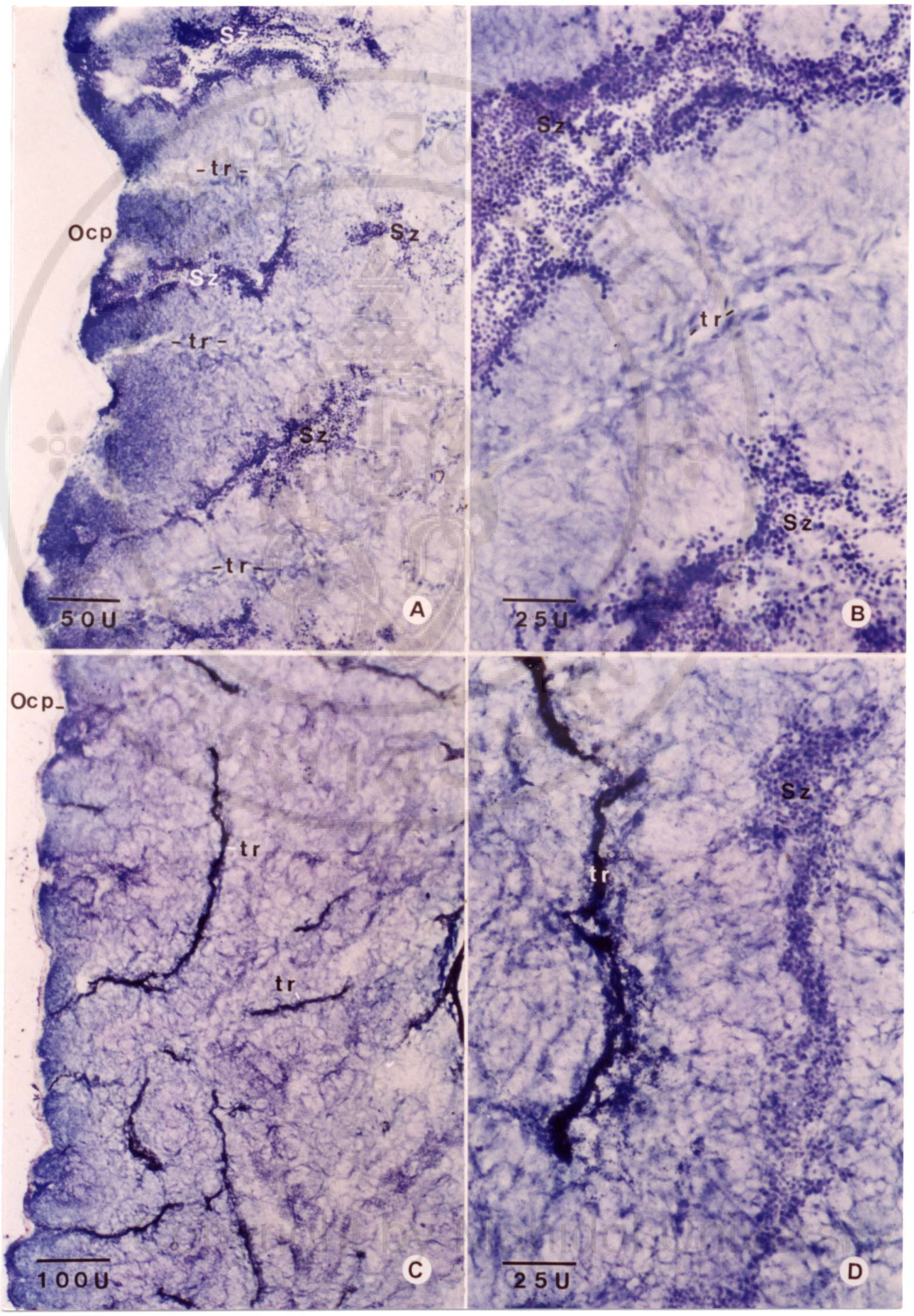
Sz
-tr-
Ocp
Sz
Sz
-tr-
Sz
-tr-
50U
A
Sz
tr
Sz
25U
B
Ocp
tr
tr
100U
C
tr
Sz
25U
D

Figure 31. Light micrographs of the testis in mature phase, stained with anti-aELH by using immunoperoxidase method.

A&B. Control sections showing no staining in the trabeculae (tr), outer capsule (Ocp), inner capsule (Icp), male germ cells and spermatozoa.

C&D. Sections stained with anti-aELH showing strong positive staining in the granulated cells (gr) and moderate staining in the trabeculae and both capsules.

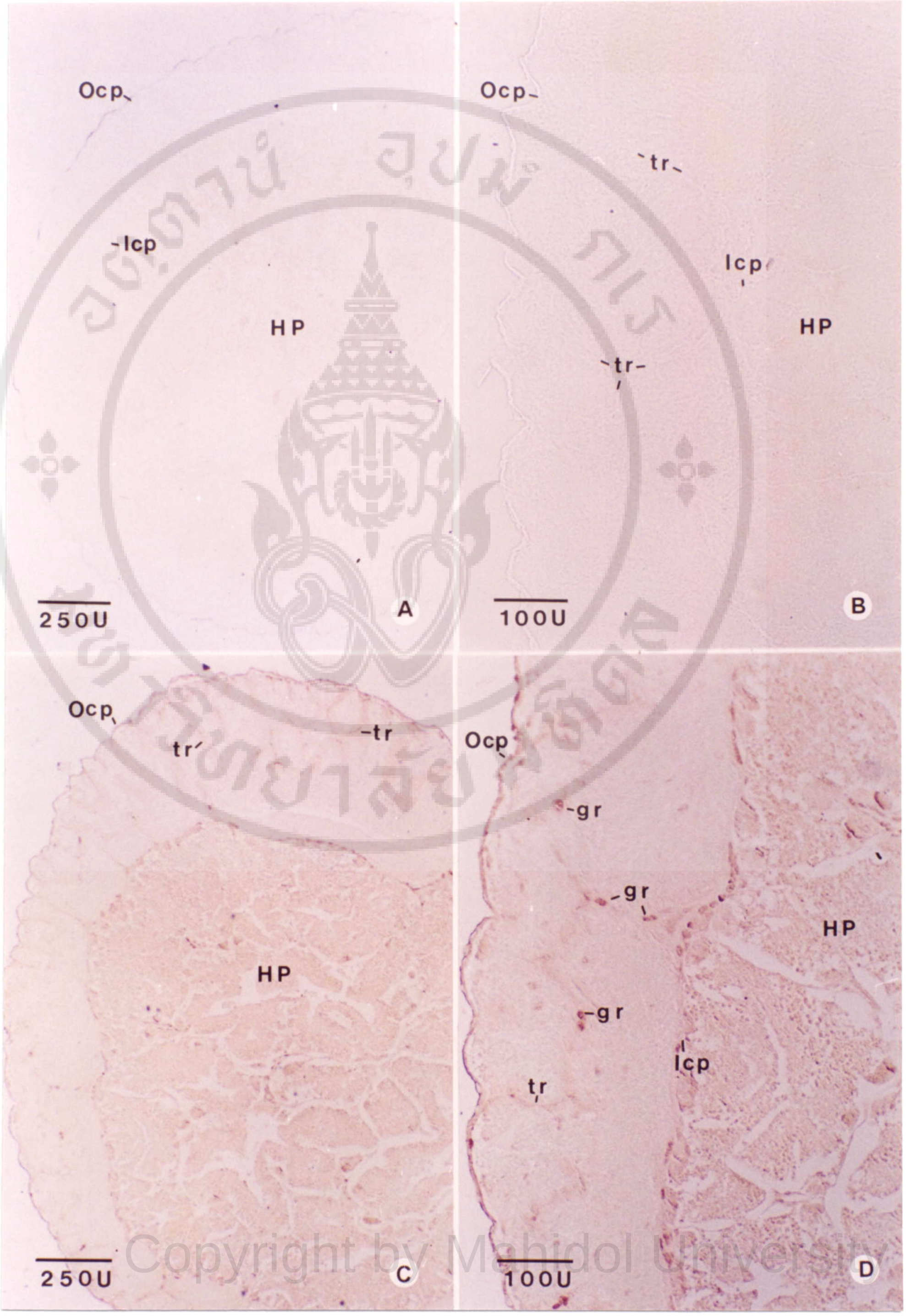
Ocp
lcp
HP
250U
A
Ocp
tr
lcp
HP
tr
100U
B
Ocp
tr
tr
HP
250U
C
Ocp
gr
gr
HP
gr
lcp
tr
100U
D

Figure 32. **A-E.** Light micrographs of the mature testis, stained with anti-aELH by using immunoperoxidase method. In A-D, the trabeculae (tr) and outer capsule (Ocp) show strong positive staining while male germ cells and spermatozoa (Sz) are not stained. In D&E, granulated cells (gr) with large granules in their cytoplasm are very intensely stained.

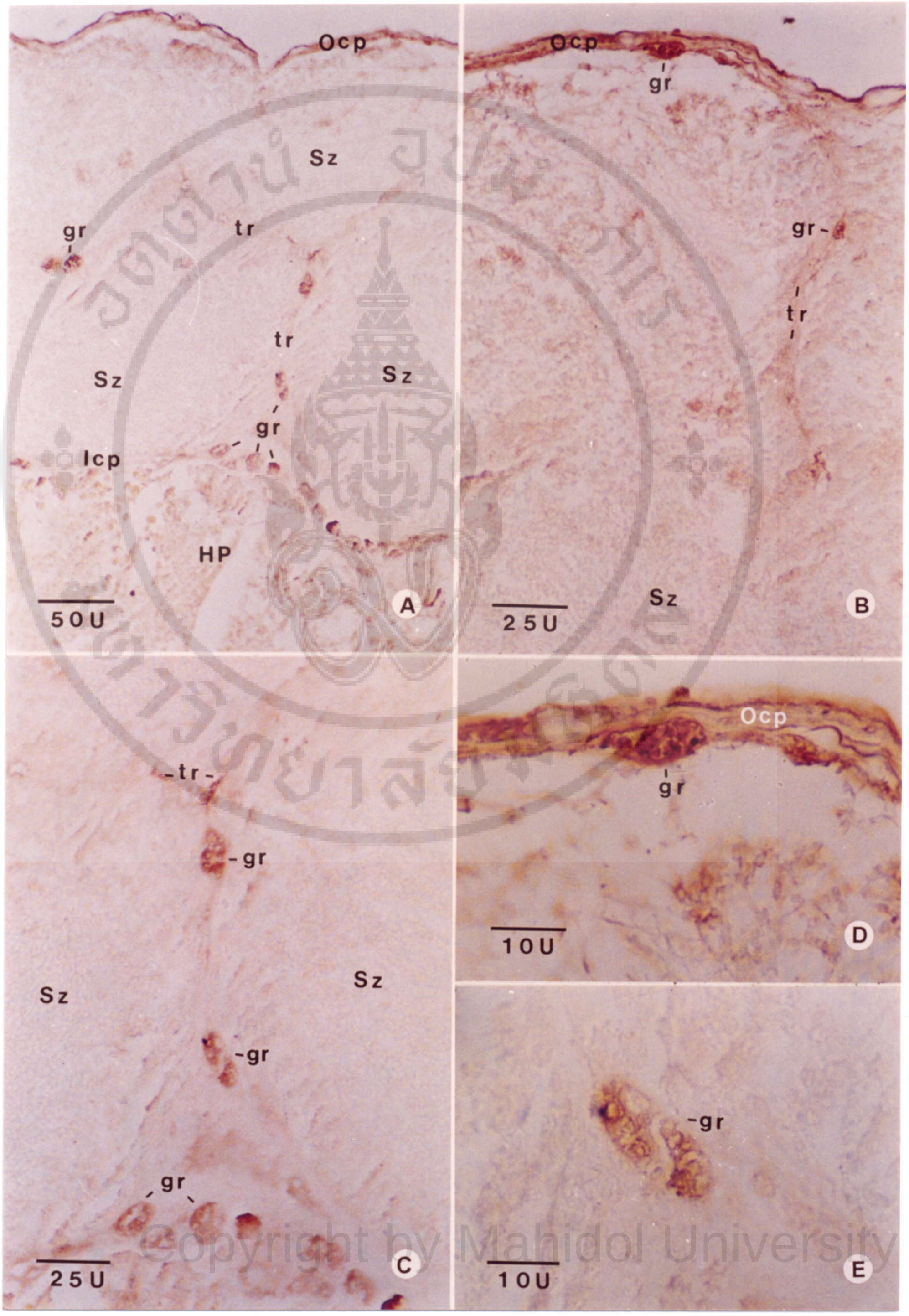
Ocp
Sz
gr
tr
tr
Sz
Sz
gr
Icp
HP
50U
A
Ocp
gr
gr
tr
Sz
25U
B
tr
gr
Sz
Sz
gr
gr
25U
C
Ocp
gr
10U
D
gr
10U
E

Figure 33. Light micrographs of the mature testis, stained with anti-aELH by using immunoperoxidase method and counter-stained with Mayer's hematoxylin.

A&B. Control sections showing no positive staining in the trabeculae (tr), outer capsule (Ocp), muscle cells (mu), male germ cells and spermatozoa (Sz).

C&D. Sections stained with anti-aELH showing strong positive staining in the muscle cells and moderate staining in the outer capsule (Ocp) and trabeculae, while male germ cells and spermatozoa are not stained.

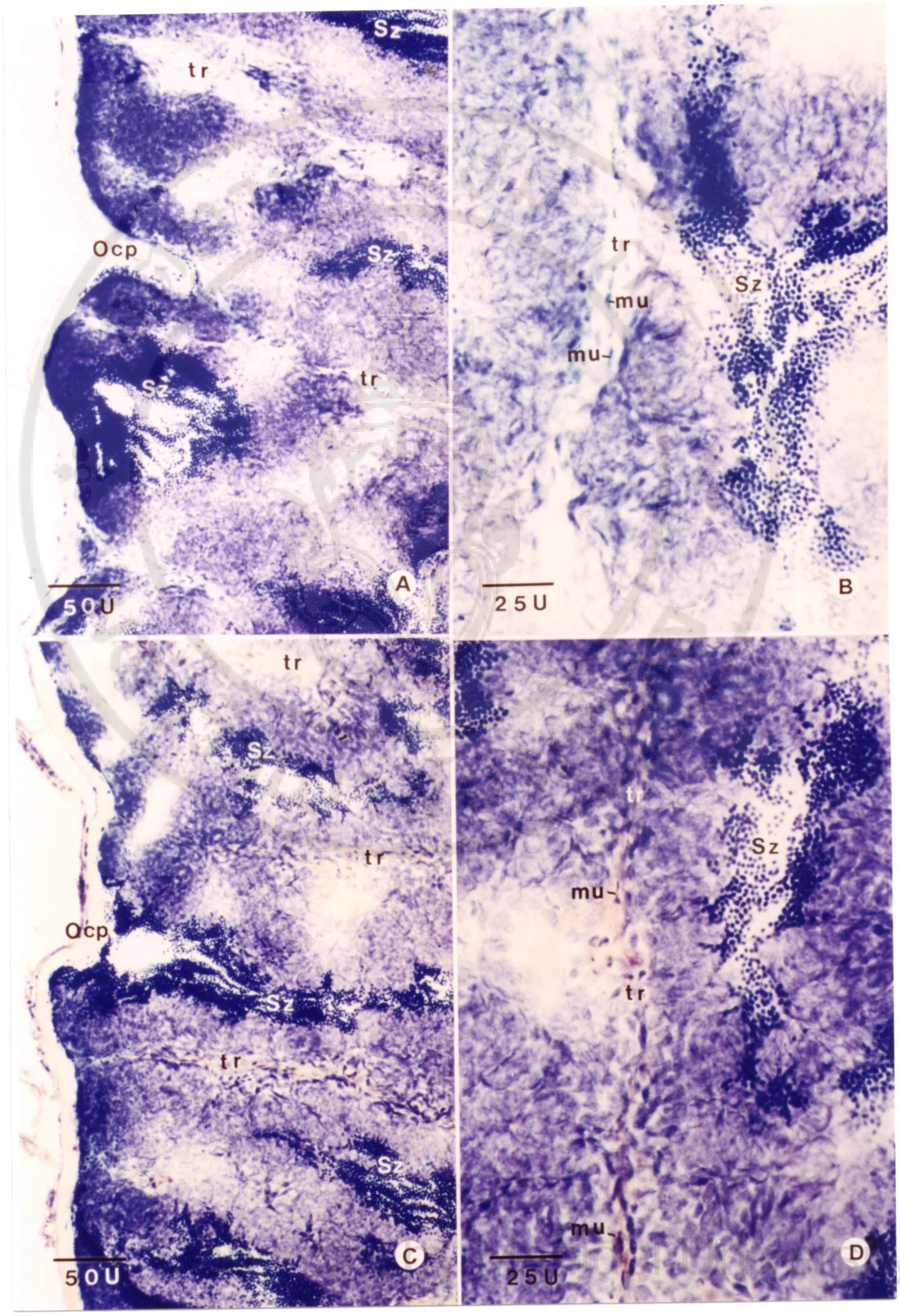
Sz
tr
Ocp
Sz
Sz
tr
50U
A
tr
-mu
mu-
Sz
25U
B
tr
Sz
tr
Ocp
Sz
tr
Sz
50U
C
tr
Sz
mu-
tr
mu-
25U
D

CHAPTER VI

DISCUSSION

Gonadal Histology and Classification of Cells in Gametogenesis

The histology of abalone species, the primitive gastropods, has been extensively studied, such as, in *H. tuberculata* since 1924 (63). In 1929, Croft showed that the basic framework of the gonad of *H.tuberculata* was composed of fibrous capsular and trabecular supports, from which germ cells appeared to generate (31). Furthermore, similar studies in other species, such as, *H. diversicolor diversicolor* (21), *H. discus hannai* (22, 23, 64), *H. rufescence* (24, 65), *H. cracherodii* (66), *H. ovina* (26, 41) and *H. asinina* (27, 28) have been performed.

In the present study, the gonadal histology of *H. asinina* was investigated by paraffin and semithin methods and light microscopy. We found that the outer layer of gonadal capsule or outer capsule was lined by a single layer of mucus-secreting epithelium which was PAS positive. This was in accordance with the observations of Martin et al.(65) and Apisawetakan et al. (67) who also found that the epithelium was not a cuticle as suggested by Young and DeMartini (24). The middle layer of gonadal outer capsule consists of several layers of alternated muscles cells and collagen fibrils, that intermingle with fibroblasts which exhibit dense ellipsoid nuclei. There are also granulated cells and nerve fibers concentrated on the inner part of the middle layer. The gonadal capsule is lined as the inner surface with a single layer of simple squamous epithelium. Within the trabeculae, there are also muscle cells, fibroblasts and granulated cells. Similar pattern of structural organization of the gonad connective tissue scaffold was confirmed by the electron microscopic study by Apisawetakan et al. (67). Within the capsules and trabeculae, the granulated cells with large endocrine granules could be one of the primary producer and/or storage site of hormone which controls reproductive activity. The muscle cells may play an important role in expelling mature oocytes by contraction of the capsules and trabeculae. The function of fibroblasts and collagen fibrils could be primarily supportive.

There have been several studies on the classification of germ cells in the oogenetic and spermatogenetic processes. Tomita (22,23) classified female germ cells into 7 stages: oogonium and 6 stages of oocytes, while male germ cells were divided into 4 stages: spermatogonium, spermatocytes, spermatid and spermatozoa, based on size and histological features. Takashima et al. (21) showed that there were 9 stages of female germ cells (oogonium and 8 stages of oocytes) and 5 stages of male germ cells (2 stages of spermatogonium, spermatocytes, spermatids and spermatozoa) in *H. diversicolor diversicolor*. Young & DeMartini (24) suggested that there were only 4 stages of female germ cells and 4 stages of male germ cells. By using TEM to study the relative abundance of various organelles, particularly ribosomes, and the development of rough endoplasmic reticulum and Golgi complex in the cells, Martin et al. (65) classified female germ cells in *H. rufescens* into 5 stages: oogonium, presynthetic oocyte, synthetic oocyte, early postsynthetic oocyte and fully developed postsynthetic oocyte. In *H. asinina*, the classification of germ cells has been studied by Apisawetakan et al. (27) under LM and Sobhon et al. (28) under LM and TEM. Female germ cells were divided into 6 stages, based on the presence of cell organelles and the possible associated synthetic activities. While male germ cells were divided into 13 stages based on the changes in the pattern of chromatin organization, the presence of cell organelles and the formation of acrosome (27, 28).

In our study of *H. asinina*, the following light microscopic characteristics have been used for dividing the stages of female germ cells: 1) the appearance of nucleus and nucleolus, 2) the clarity of nuclear membrane which is the result of the density difference between the condensed chromatin in the nucleus and the surrounding cytoplasm, 3) the basophilia in the cytoplasm of the cells caused by staining affinity to basophilic dyes which reflect the abundance of ribosomes in the cytoplasm, 4) the presence of lipid droplets, 5) the occurrence of fine blue cortical granules, and eosinophilic yolk granules, and their relative abundance and 6) the presence of jelly coat surrounding the cell membrane. By using these rather stringent morphological criteria, the cells in oogenetic units could be classified into 6 stages: oogonia (Og) and 5 stages of oocytes (Oc_1-Oc_5).

Oogonium is distinguished by the nucleus, which contains a thin rim of heterochromatin and the nucleous is small. These cells are usually concentrated in groups at the capsular side of the trabeculae. When mature oocytes are released from the ovary, these cells are the only remaining group of germ cells. During proliferative phase, there are regeneration of connective tissue trabeculae and proliferation of the cluster of Og. Thus Og could maintain a constant pool of early stem cells.

In Oc_1, the outline of nuclear membrane could not be easily seen under LM because of the intense basophilia of its cytoplasm and condensed chromatin within the nucleus. The nucleolus is present but not prominent. In Oc_2, due to the decondensation of most chromatin fibers and the increased translucence of the nucleoplasm, the nuclear boundary could be observed under LM. The nucleolus is prominent, and because of its enlargement, the nucleolar activities for ribosomal synthesis is belived to be on the increase (72). In Oc_3, the nucleus contains lampbrush chromosomes which are mostly decondensed into small fibers, so the nucleoplasm is transparent. The nucleolus is enlarged as its chromatin fibers are mostly completely uncoiled; this implies the active transcriptional as well as translational activities. In Oc_4 and Oc_5, the nucleus is completely enlarged. The chromatin is completely in euchromatic state and the nucleolus is fully enlarged and appears eosinophilic. This indicates that there are still high levels of both nuclear and nucleolar transcriptional activity.

The oocytes stained with hematoxylin and methylene blue exhibit increasing basophilia in the cytoplasm of Oc_1 and Oc_2 and decreasing basophilia in the cytoplasm of Oc_3, Oc_4 and Oc_5. It is likely that the cytoplasmic basophilia reflects the abundance of ribosomes in the cytoplasm which will prepare the cell for synthetic activities. The observation under TEM by Sobhon et al.(28) revealed that there was an increasing amount of ribosomes in the cytoplasm of Oc_1. Thus, Oc_1 may correspond to the presynthetic oocytes as described by Martin et al. (65). In our study, lipid droplets first appear in the less intense basophilic cytoplasm of Oc_2. The previous study by Sobhon et al. (28) also showed that few secretory granules probably cortical granules, start to appear around Golgi complexes indicating that Oc_2 could represent the initial synthetic oocyte. The eosinophilic yolk granules first appear in the cytoplasm of Oc_3 and later increase in number; hence the cytoplasm of Oc_3 is more reddish when compared to that of Oc_2. Moreover, the basophilic fine granules are seen scattered between yolk granules and lipid droplets in Oc_3, suggesting that it is the stage of increasing synthetic activities for both cortical and yolk granules.

In the present study, a thin jelly coat surrounding the cell membrane is first detectable in Oc_4. The cytoplasm of Oc_4 becomes increasingly eosinophilic and appears more reddish due to the staining of numerous yolk granules by eosin. The yolk granules are PAS-negative, while the jelly coat is PAS-positive as observed by Apisawetakan et al. and Sobhon et al. (27, 28). This implies that there may be very little or no carbohydrate moieties in the yolk granules, while these are the major component of the jelly coat.

Another remarkable feature of Oc_4 under LM is the appearance of a narrow bluish stripe in the cytoplasm just underneath the cell membrane, while the bluishness of most cytoplasm in much decreased in comparison to Oc_2 and Oc_3. This could be due to the high concentration of type 1 and 2 basophilic cortical granules which are translocated to this area as described by Sobhon et al. (28). Furthermore, observation at electron microscopic level revealed that these type 2 secretory granules were concentrated in the narrow cytoplasmic zone underneath the plasma membrane (28). Martin et al. (65) and Davenport (73) have suggested that extracellular membrane (the jelly coat, chorion and vitelline layer) were produced from material secreted by the developing oocyte itself. While Sobhon et al. (28) suggested further that one type of very dense cortical granules contribute their matrix to form the major part of jelly coat material.

Mature oocyte, Oc_5, is surrounded by a thick jelly coat and has increasing number of lipid droplets, yolk granules and basophilic granules in the cytoplasm. The cytoplasm of Oc_5 is laden with reddish yolk granules. Based on the size of the yolk granules, there could be 2 subgroups of the Oc_5: one containing small granules of uniform size while another contains very large granules. It is still not possible to confirm whether these are two separate stages of Oc_5, or that the latter merely represent the final stage in which small yolk granules are coalesced to form large granules. In any cases these two subgroups of Oc_5 should represent fully mature cells. Follicular cells surrounding oocytes in previous stages disappear in Oc_5. It was suggested that the absence of follicular cells might allow the detachment of Oc_5 into space between trabeculae and allow it to be released from the ovary (65). Thus, the follicular cells may play a major role in helping the adherence between oocytes and trabecula, while the former is undergoing maturation. In addition, follicular cells may be involved in nutritive function for oocytes as the number of these cells decreases when oocytes reach maturation.

Male germ cells in *H. asinina* could be classified into 13 stages according to the size, shape, appearance of chromatin, and the presence or absence of nucleolus. Sg is the earliest cell whose nucleus contains mostly euchromatin with only a thin rim of heterochromatin along the nuclear envelope, thus the nucleolus is prominent. Sg divides mitotically to give rise to primary spermatocytes, which increase in size consequently in LSc, ZSc and PSc, and decrease in size in DSc. Subsequently, the cells become enlarged in size in MSc and SSc. The chromatin condensation starts from small to larger blocks of heterochromatin that are evenly scattered throughout the nucleus in LSc and ZSc. Heterochromatin blocks are increasing in thickness and length, and become more entwined into bouquet pattern in PSc and DSc. In the MSc, chromatin appears as pairs of chromatids that are moved to the equatorial region while the SSc has heterochromatin cords that exhibit checker-board appearance. The nucleolus is prominent in the LSc and disappears in the ZSc. PSc are the numerous cells during prophase stage while MSc are the least numerous because they probably transit quickly to the next stage. In our study, SSc are quite numerous, in contrast to the general picture for secondary spermatocytes in vertebrate species. Our finding suggests that in abalone SSc may take a longer time for differentiation to the next stage and therefore there appears to be more of these cells at any time in the gonadal sections.

Four stages of spermatid could be identified in *H. asinina* based on the nuclear size, shape and chromatin condensation. St_1 and St_2 exhibit fine chromatin that are evenly dispersed throughout the nucleus. However St_1 and St_2 are different in size (6 µm, 4 µm), thus the nucleus of St_2 appears denser than that of St_1 and chromatin becomes more evenly condensed. In St_3, the chromatin fibers begin to be tightly wound together into large dense blocks, particularly along the nuclear envelope, leaving clear areas between the blocks. Eventually, the decrease in volume of nucleus and its more ellipsoid shape results in the total condensation of chromatin mass in St_4.

The two stages of spermatozoa show elongated nucleus with completely dense chromatin, thus the outline of chromatin is barely discernible. Sz_1 shows the initial formation of acrosome as a clear cap-like structure on one end of the nucleus, while exhibiting only a short tail. In Sz_2 the nucleus is elongated further and exhibits a completely formed tail that is long and points outwards from each trabecula.

Development of the Gonad

The study of maturation of the gonad in the three species of abalone in southern California based on shell length and histological changes of the gonad revealed that *Haliotis fulgens* matured as early as 3 years, *H. corrugata* at 4 years and *H. sorenseni* 5 years of age (69). Similarly, using the index from spawning induction to indicate the maturity and fecundity, it was found that *Haliotis iris* first produced mature eggs when it was about 4 years old with a shell length about 60 mm (70). In comparison to these temperate abalone species which need a relatively long time for maturation, Singhagraiwan (20, 61) found that the maturation of gonad in *H. asinina* was observed in females at 9 months old with a shell length of at least 48.5 mm for the wild broodstock, and 44.0 mm for the hatchery-reared broodstock. On the other hand, the mature gonad of males became obvious in animals with a shell length of at least 31 mm, which was about 7 ½ months old (20, 61, 62). The data in the present study indicates the same trend of development in *H. asinina* as observed by Singhagraiwan (20, 61, 62). Furthermore, detailed histological study indicates that the definitive gonads which are still undifferentiated sexually appear to be clearly separated from the hepatopancreas at 2 months. The testis could be distinguished by the presence of Sg, Sc and a few of Sz_1 at 4 months, while Og, Oc_1 and few of Oc_2 appear in the ovary at 6 months. The connective tissue starts to form small trabeculae extending into the gonad at 4 months in male and 6 months in female abalone. Another remarkable feature during this month is the relationship between the size of gonad and hepatopancreas; the hepatopancreas is relatively large when compared to the gonad. Boolootain et al. (1962) reported that, in *Haliotis cracherodii* and *H. rufesccens*, the size of hepatopancreas exhibited an inverse relation to that of the gonad (71), and they suggested that this was due to materials being mobilized from the hepatopancreas for the growth of the gonad (71). During proliferative phase, the hepatopancreas attained a maximum growth, while the gonad activity was relatively quiescent (27, 28, 29). So, the testis at 4 months is in late proliferative phase and the ovary at 6 months is in early proliferative phase.

In the present study, the testis tends to reach maturity quicker than the ovary at 7 to 8 months, the time at which St and Sz_2 are found to be abundant. The ovary tends to mature later at 11 to 12 months when it starts to contain mature oocytes (Oc_4 and Oc_5). In this period the connective tissue trabeculae increase in number and extend from the outer capsule to the inner capsule. The hepatopancreas decreases in size when compared to the gonad. Thus, the males *H. asinina* tend to reach maturity and enter reproductive cycle much earlier than females. When compared to temperate species, the age at sexual maturation for *H. asinina* occurs much sooner. This early maturation of sexual organs was also observed in other gastropods in the tropical region such as in *Achatina fulica*, where spermatogenesis with fully mature spermatozoa began at 3 months old and the mature oocyte was firstly observed at 5 months old (68).

Localization of Egg-Laying Hormone in the Gonad

The primary regulator of egg-laying activities in gastropods has been identified as neuropeptide hormones variously called egg-laying hormone (ELH) in *Aplysia*, caudo-dorsal cell hormone (CDCH) in *Lymnaea,* and abalone egg-laying hormone (aELH) in *Haliotis*. ELH has 36 amino acids and a molecular weight about 4.3 kD (51), in comparison to CDCH which has a molecular weight about 4.5 kD (52), and aELH about 4.3 kD (53). Genes encoding ELH, CDCH and aELH have been cloned (53, 74, 75). The nucleotide sequence encoding aELH of *H.rubra* was found to have a 95.4% homology with that of CDCH in *L.stagnalis,* but only 51.9% homology with that of ELH in *A.californica*. Only 1 amino acid difference was found between aELH of

H.rubra and CDCH of *L.stagnalis*, while there were 19 amino acid differences between aELH of *H.rubra* and ELH of *A.californica* (53).

The expression of the egg-laying peptide gene in the bag cells of abdominal ganglion, atrial gland, and pleural ganglion of *A. californica* has been detected by *in situ* hybridization, using radiolabelled cDNA probes to ELH mRNA (76). Some work had also been done to locate the ELH receptor within the ovotestis of *A. californica*. ELH binding-protein from ovotestis was purified by ELH affinity column chromatography, and antibodies were produced for localizing this protein in *A. californica* gonad (77). It was revealed that the cytoplasm of oocytes was the only site of immunoreactivity, which was never detected in spermatocytes and spermatozoa. In *L. stagnalis, in situ* hybridization experiments with cDNA probes revealed a high level of CDCH mRNA expression in caudo-dorsal cells in the cerebral ganglia, and the observed expression pattern correlated with immunocytochemical data which implied that CDCH was transported through the axon and released by exocytosis to the hemolymph (78, 79, 80). The expression of CDCH was not restricted to the CNS alone, but was also found in the reproductive tract, including oothecal gland, muciparous gland, and pars contorta, which are female accessory sex glands in *L.stagnalis*. In these glands the processes of positively labeled neurons terminated on the secretory cells, suggesting that they controlled the activities of these tissues (80). CDCH immunoreactive material has also been found in secretory cells of the prostate gland and sperm duct (81).

In contrast to CDCH, little is known about the origin of egg-laying hormone in abalone. Histological studies in the Japanese abalone, *H. discus hannai*, showed that the number of neurosecretory cells, especially type 1 and 7, in pleural-pedal ganglia were correlated with the induction of spawning (82). Injections of pleural-pedal and visceral ganglia crude homogenates, or the combination of both, caused female *H.discus hannai* to spawn (50). The quantity of eggs being spawned were significantly greater with the injections of homogenates from the visceral ganglion or the combination of pleural-pedal and visceral ganglia, when compared with the injection of pleural-pedal ganglion alone (50). In our preliminary study of *H.asinina* visceral ganglia, neurosecretory cells type 1 were also positively stained with anti-aELH (unpublished observation). Hence, the existing evidence implies that the abalone egg-laying hormone is mostly produced by neurosecretory cells of the nerve ganglia, particularly pleuropedal and visceral ganglia

In the present study, we were also able to detect the presence of ELH in the gonad of *H. asinina* by using 3 immunodetection methods: immunofluorescence, immunogold with silver enhancement and immunoperoxidase. By using immunofluorescence method, anti-aELH appeares to be localized in the trabeculae and capsules of the gonad in both sexes. There may be some cells in the trabeculae or in capsules that contain aELH, but we could not identify them by this method since the fluorescence of the trabeculae and capsules were quite strong so that it tended to obscure the positive cells. Consequently, we had to confirm our result by using immunogold method with silver enhancement that was simple and not time-consuming (84, 86). We found that, the granulated cells were accumulated as patches of dense gold and silver particles, which rendered them invisible as they were imperceptibly merged with the strong staining of the trabeculae and capsules. This was because autonucleation resulted in the presence of background. Furthermore,. in immunofluorescence and immunogold the jelly coat of mature oocytes showed non-specific staining due to fluorescence and non-specific binding to gold-labeled secondary antibodies. These non-specific signals tend to create a background staining that interferes with the positive signals. The last and the best method employed in our view was the use of immunoperoxidase method, since it had high specificity and suppressible endogenous peroxidase activity, which will not interfere with the positive staining. Furthermore, the sections could be counter-stained and provide easy viewing and identification of various cells types of the gonad by light microscope.

By using immunoperoxidase method, anti-aELH from *H. rubra* showed a strong cross reaction with *H. asinina* gonadal tissues. This implies that aELH may also be produced and stored in the granulated cells within the trabeculae and capsules of the gonad. Similarly, muscle cells in these connective tissue scaffolds are also stained with anti-aELH, suggesting that this group of cells also bind aELH. Coggeshall (1972) suggested that, in *Aplysia*, ELH acted directly on muscle cells to induce their contraction, which caused the expulsion of ripe oocytes from the ovary (83). From the evidence gathered in the present study we, therefore, would like to suggest that the granulated cells in the trabeculae and the capsules of gonad in both sexes of abalone can synthesize aELH. Apisawetakan et al. (2000) characterized cells in the trabeculae in the gonad of *H. asinina* under TEM. They found that there were numerous nerve processes consisted primarily of axons containing neurochemical vesicles; the axons were in closed contact with granulated cells and their branches. They suggested that the nervous system played a direct role in controlling the release of aELH by granulated cells (67). It is possible that, after being released from the granulated cells, this hormone can bind to muscle cells in the trabeculae and capsules and causes them to contract, resulting in the expelling of ripe oocytes or spermatozoa from the gonad.

The significance of the binding of anti-aELH to early stage oocytes is not known, but this hormone may also participate in the developmental process of germ cells.

CHAPTER VII

CONCLUSIONS

The results in the present study can be concluded as follows:

1. The gonad of *H. asinina*, conical organ, consists of the hepatopancreas surrounded by the testis or ovary. The connective tissue scaffold of the gonad is composed of fibro-muscular tissue. This capsule forms connective tissue trabeculae that extend into the gonad area to connect at the innermost ends with connective tissue capsule of the hepatopancreas. As a result, the gonads are partitioned into small compartments. Each trabecula contains small capillaries in the center, that are surrounded by muscle cells, collagen fibers intermingled with fibroblasts, and a substantial number of granulated cells. Each granulated cell has small spherical nucleus with ovoid shape about 10×18 μm in size and contains numerous spherical granules (about 0.3-0.6 μm in diameter) within the cytoplasm. Granulated cells are present in all areas of connective tissue scaffold; they are more numerous in the inner capsule. Each trabecula acts as an axis on which gonial and growing germ cells are attached to, while fully grown oocytes or sperm are completely detached. This unit is termed oogenetic or spermatogenic unit.

2. Germ cells in oogenetic process could be classified into 6 stages (oogonium and 5 stages of oocytes) according to the appearance of chromatin and nucleolus, the basophilic cytoplasm, the presence of lipid droplets, yolk granules, and jelly coat. Og contains a thin rim of heterochromatin along the nuclear envelope and the nucleolus is small. It is usually concentrated in groups. Oc_1 has dense chromatin in the nucleus

and intense basophilic cytoplasm; the nucleolus is present but not prominent. Oc_2 is characterized by the decondensation of chromatin fibers in the nucleus, thus the nucleolus is prominent. It shows the first appearance of lipid droplets in the less intense basophilic cytoplasm. Oc_3 exhibits the presence of eosinophilic yolk granules and increased number of lipid droplets. Oc_4 is characterized by the appearance of thin jelly coat surrounding the oocyte. It shows fine blue granules and lipid droplets in the cytoplasm. Oc_5 is distinguished by a thick jelly coat surrounding the cell membrane and there are numerous eosinophilic yolk granules and lipid droplets in the cytoplasm. Oc_5, mature oocyte, is completely detached from the trabeculae.

Male germ cells could be classified into 13 stages: spermatogonium, 5 stages of primary spermatocytes, secondary spermatocyte, 4 stages of spermatids, and 2 stages of spermatozoa, based on size, appearance of chromatin, and presence or absence of nucleolus. Sg has a thin rim of heterochroamtin along the nuclear envelope; the nucleolus is prominent. There are 4 stages of primary spermatocytes, *i.e.*, leptotene spermatocyte (LSc), zygotene spermatocyte (ZSc), pachytene spermatocyte (PSc), diplotene spermatocyte (DSc) and metphase spermatocyte (MSc). LSc and ZSc contain blocks of chromatin within the nuclei, but the nucleolus is absent in ZSc. PSc is similar to DSc, but it has a large nucleus. There are thick fibers of heterochromatin that are entwined into "bouquet pattern" within the nuclei of both spermatocytes. MSc exhibits thick chromosomes that move to the equatorial region and the nuclear membrane completely disappears. SSc shows thick chromatin blocks that are crisscrossing one another like checker-board. Spermatids consist of 4 stages, *i.e.*, St_1, St_2, St_3 and St_4. St_1 resembles St_2, with their chromatin fibers appear as fine scattered granules, but the nucleus of St_2 is smaller than that of St_1. St_3 is similar to St_4 which exhibits oval shape with eccentrically located nucleus. However, in St_3 the chromatin fibers begin to condense into dark blocks, while the chromatin fibers become completely condensed in St_4. There are 2 stages of spermatozoa, *i.e.*, Sz_1 and Sz_2. Sz_1 has an acrosome on one side of the ellipsoid nucleus with a short tail, while Sz_2 has an acrosomal cap on one side of a fully elongated nucleus with a long tail.

3. In developing *H. asinina*, the definitive gonad becomes clearly separated from the hepatopancreas at 2 months. Testis and ovary could be distinguished by the presence of their initial stages of germ cells as early as 4 months in male and 6 months in female. The testis tends to reach maturity quicker than the ovary at 7 to 8 months, the time at which spermatozoa (Sz) are found to be abundant. The ovary tends to mature at 10 to 11 months when it starts to contain mature oocytes (Oc_4, Oc_5). Thus, males tend to reach maturity and assume reproductive cycle much earlier than females.

4. The investigation of localization and distribution of ELH in the gonad of *H. asinina* are performed by using mouse polyclonal antibody to recombinant aELH of *H. rubra* for immunohistochemical detections. Anti-aELH exhibits strong bindings to granulated cells and muscle cells within the trabeculae and capsules of the gonad in both sexes. This implies that aELH may also be synthesized and stored in the granulated cells within the trabeculae and capsules of gonad. It is possible that aELH released from the granulated cells, may bind to muscle cells in the trabeculae and capsules and causes them to contract, which results in the expelling of ripe oocytes or spermatozoa from the gonad. Furthermore, the cytoplasm of immature oocytes (stage 1, 2, 3) is moderately stained, while that of mature oocyte (stage 4, 5) is only weakly stained. Thus, this hormone may also participate in the developmental process of germ cells.

REFERENCES

1. Uki N. Abalone seeding production and its theory (1). Int J Aq Fish Technol 1989; 1: 3–15.
2. FAO. Yearbook of fisheries statistics. United Nation Food and Agricultural Organization. Vol 40 Rome, 1975.
3. Nateewathana A, Hylleberge J. A survey on Thai abalone around Phuket Island and feasibility study of abalone culture in Thailand. Thai Fish Gazette 1986; 39: 177-190.
4. Tookvinart S, Leknim W, Donyadol Y, Preeda-Lampabutra Y, Perngmak P. Survey on species and distribution of abalone (*Haliotis* spp.) in Surajthani, Nakornsrithammaraj and Songkhla provinces. National Institute of Coastal Aquaculture, Department of Fisheries, Ministry of Agriculture and Cooperatives, Thailand, 1986. Technical Paper No. 1/1986.
5. Nateewathana A, Bussarawit S. Abundance and distribution of abalone along the Andaman Sea Coast of Thailand. Kasetsart J (Nat Sci) 1988; 22: 8-15.
6. Singhagraiwan T, Sasaki M. Breeding and early development of the donkey's ear abalone, *Haliotis asinina* Linne. Thai Mar Fish Res Bull 1991a; 2: 83-64.
7. Singhagraiwan T, Sasaki M. Growth rate of donkey's ear abalone, *Haliotis asinina* Linne, cultured in tank. Thai Mar Fish Res Bull 1991b; 2: 95-100.

8. Singhagraiwan T, Doi M. Seed production and culture of a tropical abalone, *Haliotis asinina* Linne. The Eastern Marine Fisheries Development Center, Department of Fisheries, Ministry of Agriculture and Cooperatives, Thailand, 1993.

9. Kakhai N, Perjamrat K. Survey on species and broodstock collection of abalone (*Haliotis* spp.) in Chonburi, Rayong and Trad provinces. Aquaculture Station, Coastal Aquaculture Division, Department of Fisheries, Ministry of Agriculture and Cooperatives, Thailand, 1992 Technical Paper No. 6/1992.

10. Sungthong S, Ingsrisawang V, Fujiwara S. Study on the relative growth of abalone, *Haliotis asinina* Linne, off Samet Island. Thai Mar Fish Res Bull 1991; 2: 15-20.

11. Poomthong T, Sahawatcharin S, Sanguanngam K. Induced spawning, seed production and juvenile growth of the donkey's ear abalone *Haliotis asinina* Linne, 1758. Phuket Mar Biol Cent Spec Publ 1997; 17 (1): 229-235.

12. Ebert EE: Abalone. In: Firth FE, editor. The encyclopedia of marine resources. New York: VanNostrand Reinhold, 1969.

13. Cox KW. Review of the abalone in California. Calif Fish and Game 1960; 46: 381-406.

14. Hahn KO. Survey of the commercially important abalone species in the world. In: Hahn KO, editor. Handbook of culture of abalone and other marine gastropods. Boca Raton (FL): CRC Press, 1989: 3-11.

15. Lindberg DR. Evolution, distribution and systemics of Haliotidae. In: Shepherd SA, Tegner MJ, Guzman del Proo SA, editors. Abalone of the world: biology fisheries and culture. Oxford: Blackwell Scientific, 1992: 3-18.

16. Imai T. Aquaculture in shallow seas: progress in shallow sea culture. Part IV. New Delhi: Amerind. 1977: 367-410.

17. Cox KW. California abalone, Family Haliotidae. Fish Bull 1962; 118: 1-133.

18. Fallu R. Abalone farming. Oxford: Blackwell Scientific, 1991: 195p.

19. Ino T. Abalone and their industry in Japan. In: Ino T, editor. Fisheries in Japan: abalone and oyster. Tokyo: Japan Marine Products Photo Materials Association, 1980.

20. Singhagraiwan T, Doi M. Spawning pattern and fecundity of the donkey's ear abalone, *Haliotis asinina* Linne, observed in capacity. Thai Mar Fish Res Bull 1992; 3: 61-9.

21. Takashima F, Okuno M, Nichimura K, Nomura M. Gametogenesis and reproductive cycle in *Haliotis diversicolor diversicolor* Reeve. J Tokyo Univ Fish 1978; 1: 1-8.

22. Tomita K. The maturation of the ovaries of the abalone, *Haliotis discus hannai* Ino, in Rebun Island, Hokkaido, Japan. Sci Rep Hokkaido Fish Exp Sta 1967; 7: 1-7.

23. Tomita K. The testis maturation of the abalone, *Haliotis discus hannai* Ino, in Rebun Island, Hokkaido, Japan. Sci Rep Hokkaido Fish Exp Sta 1968; 9: 56-61.

24. Young JS, DeMartini JD. The reproductive cycle, gonadal histology and gametogenesis of the red abalone, *Haliotis rufescens* (Swainson). Calif Fish and Game 1970; 56: 298-309.

25. Bussarawit S, Kawintertwathana P, Nateewathana A. Preliminary study on reproductive biology of the abalone (*Haliotis varia*) at Phuket, Andaman Sea Coast of Thailand. Kasetsart J (Nat Sci) 1990; 24: 529-539.

26. Jarayabhand P, Jew N, Manasveta P, Choonhabandit S.Gametogenic cycle of abalone *Haliotis ovina* Gmelin 1791 at Khangkao Island, Chon-buri Province. Thai J Aqua Sci 1994; 1: 34-42.

27. Apisawetakan S, Thongkukiatkul A, Wanichanon C, Linthong V, Kruatrachue M, Upatham ES, Poomthong T, Sobhon P. The gametogenic processes in a tropical abalone, *Haliotis asinina* Linnaeus. J Sci Soc Thailand 1997; 23: 225–240.

28. Sobhon P, Apisawetakan S, Chanpoo M, Wanichanon C, Linthong V, Thongkukiatkul A, Jarayabhand P, Kruatrachue M, Upatham ES, Poomthong T. Classification of germ cells, reproductive cycle and maturation of gonads in *Haliotis asinina* Linnaeus. Science Asia 1999; 25: 3-21.

29. Kruatrachue M, Apisawetakan S, Upatham ES, Sobhon P, Sawatpeera S, Singhakaew S, Ingsrisawang V, Singhagraiwan T. The reproductive cycle of the Thai abalone, *Haliotis asinina* Linnaeus. J Med Appl Malacol, 1999; (in press).

30. Hahn KO. Gonad reproductive cycle. In: Hahn KO, editor. Handbook of culture of abalone and other marine gastropods. Boca Raton (FL): CRC Press, 1989: 13-39.

31. Croft DR. *Haliotis*. L.MBC mem: Liverpool University Press, 1929: 174p.

32. Purchon RD. Reproduction. In: Purchon RD, editor. The biology of mollusca. Vol 47 Oxford: Academic Press, 1968: 238–269.

33. Nash CE. The production of abalone. In: Nash CE, editor. Production of aquatic animals: crustaceans, molluscs, amphibians and reptiles. Amsterdam: Elsevier Science, 1991.

34. Morse DE, Duncan H, Hooker N, Morse A. Hydrogen peroxide induced spawning in molluscs, with activation of prostaglandin endoperoxide synthetase. Science 1977; 196: 298-300.

35. Singhagraiwan T. Study on the optimum rearing density of juvenile donkey's ear abalone (*Haliotis asinina* Linne). The Eastern Marine Fisheries Development Center, Marine Fisheries Division, Department of Fisheries, Ministry of Agriculture and Cooperatives, Thailand, 1992. Technical Paper No. 36/1992.

36. Singhagraiwan T. Comparative study on the growth and survival of juvenile donkey's ear abalone (*Haliotis asinina*) in different rearing system. The Eastern Marine Fisheries Development Center, Marine Fisheries Division, Department of Fisheries, Ministry of Agriculture and Cooperatives, Thailand, 1993. Technical Paper No. 37/1993.

37. Raven CP. Development. In: Wilbur KM, Yonge CM, editors. Physiology of mollusca. Vol 1 New York: Academic Press, 1964: 165–188.

38. Leighton DL. Laboratory observations on the early growth of the abalone, *Haliotis sorenseni*, and the effect of temperature on larval development and settlement success. Fish Bull 1972; 70: 373-381.

39. Leighton DL. The influence of temperature on larval and juvenile growth in three species of southern California abalone. Fish Bull 1974; 72: 1137-1145.

40. Girard A. La reproduction de l'ormeau *Haliotis tuberculata* L. Rev Trav Inst Peches Marit 1972; 36: 163-184.

41. Minh LD. Reproductive cycle of *Haliotis ovina* Gmelin, 1791 in Nha Trang Bay, south central Vietnam. Phuket Mar Biol Cent Spec Publ 1998; 18(1): 99-102.

42. Joosse J. Evolutionary aspects of the endocrine system and of the hormone control of reproduction of molluscs. In: Barrington EJW, editor. Hormones and evolution. Vol 1 New York: Acadamic Press, 1979: 57-119.

43. Scharrer B. Ueber dat hanstromsche organ x bei opisthobranchiern. Pubbl Staz Napoli 1935; 15: 132-142.

44. Laviolettle P. Role dela gonad dan la morphogenese du tractus genital, chez quelques mollusques Limacide et Arionidae. Compt Rend Acad Sci 1950; 231: 1567–1569.

45. Kupferman I. Stimulation of egg-laying: possible neuroendocrine functions of bag cells of abdominal ganglia of *Aplysia californica.* Nature 1967; 216: 814-815.

46. Arch S. Neuroendocrine regulation of egg-laying in *Aplysia californica.* Am Zool 1976; 16: 167-175.

47. Geraerts WPM, Bohlken S. The control of ovulation in the hermaphrodite freshwater snail *Lymnaea stagnalis* by the neurohormone of the caudodorsal cells. Gen Comp Endocrinol 1976; 28: 350-357.

48. Ram JL. Hormonal control of reproduction in *Busycon*: Laying of egg capsules caused by nervous system extracts. Biol Bull 1977; 152: 221-232.

49. Ram JL, Ram ML, Davis JP. Hormonal control of reproduction in *Busycon*: Laying of egg-containing capsules caused by nervous system extracts and further characterization of the substance causing capsule-laying. Biol Bull 1982; 162: 360-370.

50. Yahata T. Induced spawning of abalone (*Nordotis discus* Reeve) injected with ganglional suspension. Bull Jap Soc Sci Fish 1973; 39: 1117-1122.

51. Chiu AY, Hunkapiller MW, Heller E, Stuart DK, Hood LE, Strumwasser F. Purification and primary structure of the neuropeptide egg-laying hormone of *Aplysia californica*. Proc Natl Acad Sci USA 1979; 76: 6656-6660.

52. Ebberink RHM, Van Loenhout H, Geraerts WPM, Joosse J. Purification and amino acid sequence of the ovulation neurohormone of *Lymnaea stagnalis*. Proc Natl Acad Sci USA 1985; 82: 7767-7771.

53. Wang L, Hanna PJ. Isolation, cloning and expression of a DNA sequence encoding an egg-laying hormone of the blacklip abalone (*Haliotis Rubra* Leach). J Shellfish Res 1998; 17 (3): 789-793.

54. Dogterom GE, Van Loenhout H. Specificity of ovulation hormone of some basommatophoran species studied by means of iso-and heterospecific injection. Gen Comp Endocrinol 1983; 52: 121-125.

55. Ram JL. Interspecific induction of egg-laying in Hawaiian aplysiids. Gen Comp Endocrinol 1982; 47: 522-528.

56. Ram JL, Ram ML. Synthetic egg-laying hormone of *Aplysia*: Quantitative studies of induction of egg laying in *Stylocheilus* and of the activation of *Aplysia* buccal neuron B16. Comp Bioc C 1989; 92: 131-134.

57. Ram JL, Ram ML, Smith S, Croll RP. Peptidergic and serotonergic mechanisms regulating spawning and egg-laying behavior in gastropods and bivalves. Malacol Rev 1997; 30: 1-23.

58. Choquet M. Study of life cycle and sexual inversion in *Patella vulgata* L. (prosobranch, gastropod, mollusk). Gen Comp Endocrinol 1971; 16: 59-73.

59. Fretter V. Prosobranchs. In: Tompa AS, Verdonk NH, Van der Biggelaar JAM, editors. The mollusca. New York: Acadamic Press, 1984: 1-45.

60. Uki N, Kikuchi S. Regulation of maturation and spawning of an abalone, *Haliotis* (Gastropoda) by external environmental factors. Aquaculture, 1984; 39: 247–261.

61. Singhagraiwan T. The experiment on breeding and nursing of donkey's ear abalone (*Haliotis asinina* Linne). The Eastern Marine Fisheries Development Center, Marine Fisheries Division, Department of Fisheries, Ministry of Agriculture and Cooperatives, Thailand, 1989a. Technical Paper No. 21/1989a.

62. Singhagraiwan T. Study on growth rates of donkey's ear abalone (*Haliotis asinina* Linne). The Eastern Marine Fisheries Development Center, Marine Fisheries Division, Department of Fisheries, Ministry of Agriculture and Cooperatives, Thailand, 1991. Technical Paper No. 28/1991.

63. Stephenson TA. Notes on *Haliotis tuberculata.* J Mar Biol Assoc UK 1924; 13 (2): 480-495.

64. Lee TY. Histological study on gametogenesis and reproductive cycle of the Korean coasts. Bull Pusan Fish Coll 1974; 14 (1); 55.

65. Martin GG, Romero K, Miller-Walker C. Fine structure of the ovary in the red abalone *Haliotis rufescens* (Mollusca: Gastropoda). Zoomorphology 1983; 103: 89-102.

66. Webber HH, Giese AC. Reproductive cycle and gametogenesis in the black abalone *Haliotis cracherodii* (Gastropoda: Prosobranchiata). Mar Biol 1969; 4: 152-159.

67. Apisawetakan S, Chanpoo M, Wanichanon C, Linthong V, Kruatrachue M, Upatham ES, Poomthong T, Sobhon P. Characterization of trabecular cells in the gonad of *Haliotis asinina* Linnaeus. J Shellfish Res (submitted).

68. Ngowsiri U. Sretarugsa P, Kruatrachue M, Chavadej J, Upatham ES. Development of, and seasonal changes in, the reproductive system of *Achatina fulica*. J Sci Soc Thailand 1989; 15:237-249.

69. Tutschulte T, Connell JH. Reproductive biology of three species of abalone (*Haliotis*) in southern California. Veliger 1980; 23: 195-206.

70. Poore GCB. Ecology of New Zealand abalones, *Haliotis* species (Mollusca: Gastropoda). New Zealand. J Mar and Freshwater Res 1973; 7 (1); 67-84.

71. Boolootian RA, Farmanfarmaian A, Giese AC. On the reproductive cycle and breeding habits of two system species of *Haliotis*. Biol Bull 1962; 122: 183-193.

72. Schwarzacher HG, Wachtler F. The nucleolus. Anat Embryol 1993; 188: 515-536.

73. Davenport R. Basic ribonucleoprotein granules in the *Haliotis* oocyte. Exp Cell Res 1967; 47: 606-607.

74. Scheller RH, Jackson JF, McAllister LB, Rothman BS, Mayeri E, Axel R. A single gene encodes multiple neuropeptides mediating a stereotyped behavior. Cell1983; 32: 7-22.

75. Vreugdenhil E, Jackson JF, Bouwmeester T, Smit AB, Van Minnen J, Van Heerikhuizen H, Klootwijk J, Joosse J. Isolation, characterization and evolutionary aspects of a cDNA clone encoding multiple neuropeptides involved in the stereotyped egg-laying behavior of the freshwater snail *Lymnaea stagnalis*. J Neurosci 1988; 8: 4181-4191.

76. McAllister LB, Scheller RH, Kandel ER, Axel R. *In situ* hybridization to study the origin and fate of identified neurons. Science 1983; 222: 800-808.

77. Choate JVA, Kruger TE, Micci M-A, Blankenship JE. Isolation of an egg-laying hormone-binding protein from the gonad of *Aplysia californica* and its localization in oocytes. J Comp Physiol A 1993; 173: 475-485.

78. Dirks RW, Raap AK, Van Minnen J, Vreugdenhil E, Smit AB, Van der Ploeg M. Detection of mRNA molecular coding for neuropeptide hormones of the pond snail *Lymnaea stagnalis* by radioactive and non-radioactive *in situ* hybridization: a model study for mRNA detection. J Histochem Cytochem 1989; 37: 7-14.

79. Dirks RW, Van Dorp AGM, Van Minnen J, Fransen JAM, Van der Ploeg M, Raap AK. Ultrastructural evidence for the axonal localization of caudodorsal cell hormone mRNA in the central nervous system of the mollusc *Lymnaea stagnalis*. Micros Res 1993; 25: 12-18.

80. Van Minnen J, Van der Haar C, Raap AK, Vreugdenhil E. Localization of ovulation hormone-like neuropeptide in the central nervous system of the snail, *Lymnaea stagnalis* by means of immunocytochemistry and *in situ* hybridization. Cell Tiss Res 1988; 251:477-484.

81. Van Minnen J, Dirks RW, Vreugdenhil E, Van Diepen J. Expression of the egg-laying hormone genes in peripheral neurons and exocrine cells in the reproductive tract of the mollusc, *Lymnaea stagnalis*. Neuroscience 1989; 33: 35-46.

82. Hahn KO. Review of endocrine regulation of reproduction in abalone *Haliotis* spp. In: Shepherd SA, Tegner MJ, Guzman del Proo SA, editors. Abalone of the world. USA: Blackwell Scientific, 1992: 49-56.

83. Coggeshall RE. The muscle cells of the follicle of the ovotestis in *Aplysia* as the probable target organ for bag cell extracts. Am Zool 1972; 12: 521-523.

84. Lucocq JM, Roth J. Colloidal gold and colloidal silver-metallic markers for light microscopic histochemistry. In: Bullock GR, Petrusz P, editors. Techniques in immunocytochemistry. Vol 3 London: Academic Press, 1985: 203-236.

85. Wordinger RJ, Miller GW, Nicodemus DS. Manual of immunoperoxidase techniques. Chicago: American Society of Clinical Pathologists Press, 1983: 73p.

86. Van de Plas P, Leunissen JLM. Ultrasmall gold probes: Characteristics and use in immuno(cyto)chemical studies. In: Asia DJ, editor. Methods in cell biology. Vol 37 San Diego: Academic Prees, 1993: 241-257.

87. Humason GL. Animal tissue techniques. San Francisco: W.H. Freeman and Company, 1967: 569p.

BIOGRAPHY

NAME	Mrs. Malee Chanpoo
DATE OF BIRTH	August 1, 1967
PLACE OF BIRTH	Bangkok, Thailand
INSTITUTIONS ATTENED	Mahidol University, 1986-1990: Bachelor of Science (Nursing) Mahidol University, 1997-2000: Master of Science (Anatomy)
RESEARCH GRANT	Thailand Research Fund (Senior Research Scholar Fellowship to Prof. Dr. Prasert Sobhon)